

# HAND SURGERY

Q U A R T E R L Y



## FROM THE PRESIDENT

### Workmanship in Practice



SUSAN MACKINNON, MD

**A**s keynote speaker at the American Society of Reconstructive Microsurgery in 2004 and at the Plastic Surgery Research Council in 2005, Ralph Manktelow, MD spoke on competitive rowing and woodworking and their analogies to surgery. He made reference to David Pye, who was a British architect, professor and furniture designer at the Royal College of Art in London. Pye published his book, *The Nature and Art of*

*Workmanship*, in 1968.<sup>1</sup> Impressed with Ralph's talk; I ordered this book for my father who is a wood carver and bronze sculptor. I read

the book first, myself, and can understand why Ralph was so impressed. In his book, Pye discusses the concept of 'workmanship of risk' where the quality of work is dependent on judgment, dexterity and care. He uses the term 'workmanship of risk' because at any moment whether due to lack of attention, inexperience or accident, the workman may ruin the job. Pye describes the opposite of 'workmanship of risk' as 'workmanship of certainty'. Here the quality of the result is determined before the work is made, such as seen with automated mass-production.

The analogy of wood working with surgery is obviously appropriate on many levels. What I found most compelling about Pye's book is his distinction between the 'workmanship of risk' and 'workmanship of certainty'. Aficionados of handmade articles will recognize the frequently quoted disclaimer, 'subtle flaws and differences are part of the charm of this hand crafted piece'. Such 'flaws' in a work of art will increase value of the piece but in a surgical procedure may be the stimulus for legal action. The work we do with our hands is certainly a 'workmanship of risk', but our patients want

and expect a 'workmanship of certainty'. This disconnect is likely the source of many lawsuits, as patients expect 'risk free' surgical procedures and surgical results with the uniformity of mass production that even the master surgeon is not always able to deliver. It is, of course, our obligation to minimize the risk and we all have our own list of qualities that make an excellent surgeon: knowledge, clinical judgment, honesty, surgical dexterity, caring, focus, and attention to detail.

Being a student of yoga for the last two years, I have come to understand that its philosophy has a tremendous application to surgery and may help to decrease the risk of errors. The practice of yoga has been passed on from teacher to student for five thousand years. First and foremost, yoga is a mental or inner discipline that must be practiced with full awareness. Judith Lasater, PhD outlines some of these principles.<sup>2</sup> Most have an analogy to surgery. 1) Be in the present moment, with no thoughts of the past or future. This quality allows the focused surgeon to lift his/her head up at the end of a difficult case and wonder where the hours have gone. Focusing on the surgical procedure and blocking out personal issues from the past or problems anticipated in the future offers the patient the surgeon's undivided attention. 2) Be mindful, especially as procedures, with experience and practice, become

*continued on page 4*



The AAHS 2006 Annual Meeting will take place at the Loews Ventana Canyon Resort, nestled by the picturesque mountains of Coronado National Forest outside of Tucson, AZ. For a quick preview, see the Program at a Glance, which starts on page 6.

This quarter we have on offer a rare treat- a glimpse into the workings of a premier medical illustrator. Elizabeth Roselius has been the illustrator for each of the five editions of Green's *Operative Hand Surgery*, long the bible of our specialty (supplanting the various editions of Bunnell's text; now challenged by other volumes, not least that co-edited by our own past President Richard Berger).

The profession of medical illustrator traces its roots to antiquity. There is a painting on the wall of the tomb of Ipuy, a sculptor in the era of Pharaoh Ramses II, depicting the reduction of a shoulder dislocation by what we now call the Kocher maneuver (see <http://www.trauma.org/history/egypt.html>). From this unknown Egyptian artist, and similar unknown illustrators of other ancient medical texts, through

Jan van Calcar, who aided Vesalius in illustrating the first modern anatomic texts (see <http://vesalius.northwestern.edu>), to our own day, medical artists have enlightened surgeons and conveyed information in ways that mere words, and often photographs, can hardly convey. Try understanding the anatomy of Dupuytren's cords from surgical photos, or verbal descriptions. Our understanding of these structures is based almost entirely on artists' renderings, effectively composites of sequential dissection snapshots, which can only be assembled into a coherent whole graphically.

Among this small but talented band of professionals, Elizabeth Roselius stands out for her skill and dedication. Those of us who have planned surgery based on her illustrations, and the patients who have benefited from that surgery, owe her a debt of gratitude that can never be truly repaid. Ms. Roselius has contributed the following brief overview of how she does what she does, with, of course, illustrations. I hope you enjoy it.



PETER C. AMADIO MD

## Illuminating Medical Text

"Medical illustrators draw what cannot be seen, watch what has never been done and tell thousands about it without saying a word." This quote from the Association of Medical Illustrators' web site describes a group of individuals dedicated to enhancing communication in the healthcare industry. A unique combination of interest in science and artistic talent distinguishes those of us lucky enough to have found this profession and who make medical illustration our career.

The field traces its American history back to the late 19th and early 20th century when German artist Max Brödel founded the first school of medical illustration at Johns Hopkins. The impact of the work of the 20th century illustrators on medical education cannot be discounted. Most physicians, when recalling their days in medical school, will vividly remember the work of such medical illustrators as Frank Netter, MD and his Ciba Collection of Medical Illustrations.

For the hand surgeon in academia publishing research papers and the private practitioner looking to enhance his patient education materials, the need exists to locate and establish a relationship with a competent medical illustrator. Chosen carefully, this person becomes a valuable asset to a physician's practice. While medical photography plays an absolutely necessary role in biomedical communications, photography is best reserved for case specific documentation of clinical specimens and pathology or for medical photo-journalistic shots. Medical illustration by nature is more subjective, allowing the artist to emphasize important information via the selective use of color, contrast, shadows, details or operative instrument placement. Extraneous background details can be de-emphasized so that the viewer immediately focuses on the pertinent anatomy and surgical action which is taking place.

How does one find a "competent and qualified" medical illustrator? Let me begin by saying that rarely is it in your best interest to use the least expensive graphic artist you can find. In the long run you get what you pay for and you'll be spending many a frustrating hour explaining anatomy or




Figure 1: Surgeon's reference sketch. Information for the artist, but not appropriate for publication.

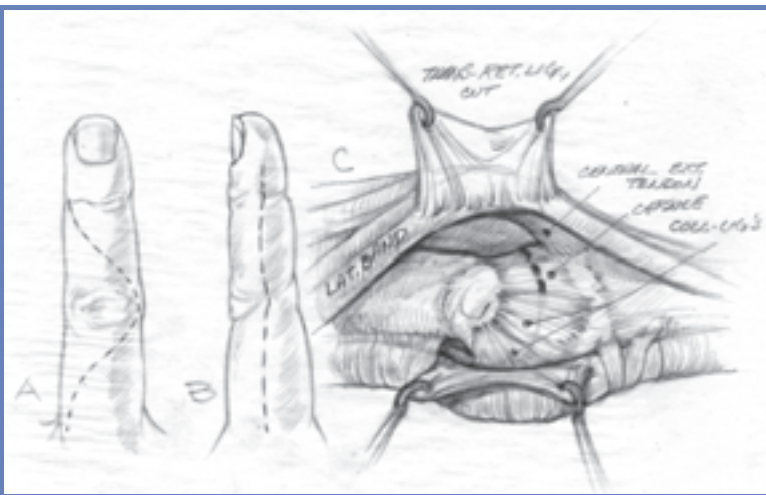


Figure 2: Preliminary pencil sketch for approval.

surgery to this person. Your time's too valuable not to hire a professional.

The best resource for finding an illustrator is through the Association of Medical Illustrators. The majority of AMI members have a master's degree from one of the six accredited graduate programs in the US and Canada. These illustrators have an undergraduate background in science and art and have completed graduate programs which include medical science courses such as human gross anatomy, pathology, physiology, embryology, and histology and art and theory courses in surgical illustration, anatomical and histological illustration, computer graphics, instructional design and 3D modeling. Members can also attain an additional "certified" status from the Association by attending continuing education classes and taking a certification exam.

On the AMI web site ([www.ami.org](http://www.ami.org)) illustrators can be found using the Member Search function. They can be located by name, geographic area and professional specialty. Also, since 1982 the AMI has annually published and distributed to art buyers the Medical Illustration Source Book. Illustrators who wish to advertise in this publication purchase page space, which can be viewed online by going to the Source Book web site ([www.medillsb.com](http://www.medillsb.com)). Here too a search function is available allowing you to search by medical specialty, market, style/technique, and artist/company. Another web site, Indexed Visuals, (

Figure 3: Final drawing without publisher-added labels.

suals.com) is a good resource. This site allows for viewing of artists' portfolios.

Once you've selected someone you want to work with it's time to get more specific with them about the project details. Let the artist know what information you'll be supplying to them. In an ideal world it'd be great if the artist could personally observe the procedure you want illustrated. The more realistic scenario is that they'll be working from a draft of your manuscript plus operative photos or video, pertinent reference material and even your rough sketches. (Fig. 1) I find the more reference material a physician can supply the less time I have to spend doing research. Producing the final renderings is actually the easy part. Most of an artist's time is involved in insuring that the preliminary sketches are anatomically and surgically correct.

You'll need to agree on a delivery timeline for preliminary sketches and finals in order to meet your deadlines. The artist needs to know how the work will be used—in print, on the internet, etc.—as this dictates the sizing and medium used, which can, in turn, effect the pricing. Keep in mind that the more ways you plan on using the draw-

ings, the higher the price. If you or your publisher wants to use the illustrations in print, worldwide, in all editions and in every conceivable electronic format the illustrator will expect to be compensated accordingly. You're not paying for just "talented hands" but for the medical illustrator's expertise in understanding, translating and depicting medical information in the clearest manner possible. Illustrators are, in effect, a visual "author" and their works are their copyrighted property, which you or your publisher are licensing. (The exception to this is if you're working with an illustrator employed by your hospital or medical school. In that case, the institution then owns the copyrights.)

Once you have a clear mutual understanding of what's expected of you and the artist you can proceed to the fun stuff. Plan ahead

*continued on page 4*

## EDITOR'S DESK

*continued from page 3*

and send the illustrator your reference material as early as possible. You don't want to pay a rush fee or miss a publishing deadline because you left the visuals to the last moment. The illustrator will send preliminary pencil sketches (Fig. 2) or computer layouts back to you for approval and/or alteration. Remember to look at these closely. Usually anything beyond one or two sketch revision cycles and the artist will have to start charging you for this additional work. Delays caused by multiple revisions can also throw off the production schedule. Changes to final artwork are even more time-consuming and costly to say nothing of the aggravation factor, so by all means avoid this scenario.

Depending on what's required, the illustrator will send finals in the form of original artwork or digital files directly to you or to your publisher. You should review the finals one last time before they're submitted for publication or web placement. (Fig. 3)

Using medically accurate visuals to supplement your written word clarifies and reinforces the information you want to communicate to your peers and patients. The addition of a qualified medical illustrator to the list of medical professionals you work with is well worth considering. **H**

*Elizabeth Roselius, MS, FAMI works out of her studio, Elizabeth Roselius Medical Art, in Allentown, NJ. She's the primary illustrator on 14 orthopedic texts, the most recent being the 5th edition of Green's Operative Hand Surgery. Her web site is [www.medical-art.net](http://www.medical-art.net).*



**Elizabeth Roselius, MS, FAMI**

## FROM THE PRESIDENT

*continued from page 1*

easier to do: there can never be a 'here we go again' attitude. Each case must be treated as your first case, with attention to detail even for, and perhaps especially, the smallest and routine activities. The placement of a drain, pain pump or the injection of local anesthetic must be always done with the same care as the most difficult parts of the procedure. 3) Yoga is a journey—so is surgery—and even after 20 years of practice, I am constantly learning new things about peripheral nerve anatomy and healing.

Does any of this have anything to do with the AAHS? At the summer Board Meeting, we unanimously agreed to explore the concept of establishing a mentorship program. Surgeons and therapists are crafts people. We learn our trade in the operating room and in the clinics from our teachers. For many of us, this hands-on training and teaching

stops after residency or fellowship. Surgery is always changing and new techniques are constantly evolving. To decrease the risk of our trade we must continue to learn. With this new mentor program, surgeons and therapists can visit an association member with expertise in a particular technique and observe, step-by-step, the details of a procedure. A list of surgeons with expertise in specific operative procedures will be available to members, who can then arrange to spend a day in the operating room with their AAHS surgical mentor. The therapists will offer a similar experience. This one-on-one mentorship program is in evolution and the co-chairs of our educational committee Andrew Lee and Michael Neumeister are currently working out the details. I am sure Mike and Andy would welcome your thoughts and you will be hearing more about the mentor program soon.

At the Board Meeting, Dick Berger brought us up to date on the tremendous work that he has done with La Federación de Organizaciones del Cuidado de Mano de Centro y Norte America/Federation of Central and North American Hand Care Organizations. Lynn Bassini, OTR, Miguel Saldana, MD and Jose Ortiz, MD will be our representatives to La Federación. Dick is optimistic that the first meeting will take place in conjunction with the Association meeting in Puerto Rico in 2008. We are all grateful to Dick for forging this new relationship with our hand colleagues. In the same spirit, this September, Dick and Brad Meland will be the keynote speakers at the Mexican Society for Surgery of the Hand. Congratulations, gentlemen!

Christine Novak, our program chair, has set an outstanding program for the thirty-sixth annual meeting, Challenges in Hand Surgery. Our keynote speakers, Peter Amadio, MD and Jeff Lichtman, PhD, will speak on "Three Decades of Tendon

## HAND SURGERY QUARTERLY

**President**  
Susan Mackinnon, MD

**Editor**  
Peter C. Amadio, MD

**Executive Director**  
Laura Downes Leeper, CAE

**Managing Editor**  
Anne B. Behrens

*Hand Surgery Quarterly* is a publication of The American Association for Hand Surgery and is published strictly for the members of AAHS. This publication is designed as a forum for open discussion and debate among the AAHS membership. Opinions discussed are those of the authors or speakers and are not necessarily the position, posture or stance of the Association.

Copyright ©2005, The American Association for Hand Surgery. All rights reserved. No portion of this newsletter may be printed without express written permission from the publisher, 20 N. Michigan Avenue, Suite 700, Chicago, IL 60602, 312-236-3307.

## HAND THERAPY PROFILE

Research: The Search for the Perfect Slide and Studying Axon Growth and Regeneration in Fluorescent Mice." Plan to be in Tucson the evening of January 10, 2006 as the Challenges in Nerve Compression Symposium starts early Wednesday morning. This will run until 2:30 in the afternoon and at 3:00, the Bio Skills Course begins. Julianne Howell has put together an outstanding hand therapy program for Saturday afternoon which will



**The Loews Ventana Canyon Resort outside of Tucson, Arizona.**

emphasize evidence based hand therapy. Laura Downes Leeper will be sending information about our silent auction. You can donate just about anything and all of the proceeds will go to the Foundation. Finally, don't forget to sign up for a spa retreat before or after the meeting. Miravel is my favorite and Canyon Ranch Spa is nearby. Until then stay focused and in the moment. Namaste. **H**

- 1 The Nature and Art in Workmanship, David Pye, Cambridge University Press: 1968.
- 2 Living Your Yoga; Finding the Spiritual in Everyday Life, Judith Lasater, Rodmell Press, Berkley CA: 2000.

### Bob Ellis, MOT, OTR/L, CHT

**Personal:** I have been involved in various aspects of hand therapy since 1977. My earliest experiences and training in hand therapy were at Emory University Hospital in Atlanta, Ga. It was there my interest in hand therapy began under the guidance of my mentor and friend Mike Brown, OTR.



**Bob Ellis, MOT, OTR/L, CHT**

**Education:** I received my B.S. degree from Kent State University (73). I later received a Masters of Occupational Therapy from Texas Women's University (84). I became a CHT in 1991.

**Employer:** University Medical Center, Tucson, AZ. since 1991.

**AAHS Involvement:** Became an affiliate member in 1990.

**Best Part of My Job:** The best part of my job is working with dedicated and professional healthcare providers. I have been very lucky over the years to have worked with some very caring people and have learned so much from so many.

**Major Accomplishments:** Receiving my OT degree and my CHT credentials. Presented at various state, regional and national conferences including AAHS, AOTA, ASHT, APTA, AZOTA and Georgia State Occupational Therapy Conference.

**Clinical Specialties:** Hand rehabilitation, splinting and ergonomic evaluations.

**Greatest Challenge:** My greatest challenge was and will always be post-op flexor tendon repairs in zone II. No matter how many years or how many flexor tendon repairs I will treat, I perceive each one as a challenge to get the optimal result for that patient.

**Three Words That Describe Me:** According to my colleagues: Professional, compassionate and innovative. **H**

Hand Surgery  
Quarterly

.....

Autumn  
2005

# AAHS 36th Annual Meeting

## Program at a Glance

January 11-14, 2006

Loews Ventana Canyon Resort, Tucson, AZ

### AAHS

Wednesday, January 11, 2006

- 7:00–8:00am Continental Breakfast
- 7:30am–2:30pm **Special Topics Day - Challenges in Nerve Compression**
- 7:30–7:45am **President/Program Chair Welcome**  
Susan Mackinnon, MD, AAHS President  
Christine Novak, PT, MS, AAHS Program Chair
- 7:45–8:00am **Histopathology of Nerve Compression**  
Susan Mackinnon, MD
- 8:00–8:20am **Patient Examination**  
Susan Mackinnon, MD  
Christine Novak, PT, MS
- 8:20–8:40am **Electrodiagnostic Studies for Nerve Compression**  
Allen Van Beek, MD
- 8:40–9:00am **Non-operative Treatment of the Patient with Nerve Compression**  
Christine Novak, PT, MS
- 9:00–9:20am **Carpal Tunnel Syndrome**  
Steven McCabe, MD
- 9:20–9:40am **Operative Treatment for Carpal Tunnel Syndrome**  
Daniel Nagle, MD
- 9:40–10:00am **Outcomes of Carpal Tunnel Syndrome, What Do We Know?**  
Kevin Chung, MD, MS
- 10:00–10:20am **Break**
- 10:20–10:40am **Operative Treatment of Recurrent Carpal Tunnel Syndrome**  
Mark Baratz, MD
- 10:40–11:00am **Cubital Tunnel Syndrome**  
Peter Amadio, MD
- 11:00–11:20am **Operative Treatment of Recurrent Cubital Tunnel Syndrome**  
Susan Mackinnon, MD
- 11:20am–12:00pm **Panel – Is It Work-Related?**  
Steven McCabe, MD, Moderator  
Kevin Chung, MD  
Peter Amadio, MD  
Ronald Palmer, MD  
Sandra Robinson, OTR CHT
- 12:00–12:20pm **Break**

- 12:20–12:40pm **The Aging Workforce**  
James Creighton, MD
- 12:40–1:30pm **Panel – Challenging Controversies in Medical Legal Issues for the Hand Surgeon**  
Ronald Palmer, MD, Moderator  
James Creighton, Jr, MD  
N. Bradley Meland, MD  
Robert Russell, MD  
William Swartz, MD
- 1:30–2:30pm **Panel – Opting Out of Medicare: Pros & Cons**  
Daniel Nagle, MD, Moderator  
Brian Adams, MD  
Michael Beatty, MD  
William Brender, MD  
M. Felix Freshwater, MD  
Richard Uhl, MD  
Nicholas Vedder, MD
- 3:00–5:00pm **Cadaver Demonstration Courses/Bioskills Workshop**  
Additional registration required. Participation is limited to 50 registrants per course/workshop.
- CD 1 **Technical Advances in Radial Head Fracture Repair and Reconstruction**  
Faculty: Mark Baratz, MD and Mark Cohen, MD  
Sponsored by KMI
- CD 2 **Entubulation – Concepts and Techniques for Peripheral Nerve Repair**  
Randip Bindra, MD  
Sponsored by Integra
- CD 3 **Current Techniques for Pyrolytic Carbon MCP/PIP/CMC Arthroplasty**  
Robert Beckenbaugh, MD  
Sponsored by Ascension Orthopedics
- CD 4 **Fixed Angle Fixation of Distal Radius Fractures**  
Faculty: TBA  
Sponsored by Hand Innovations
- CD 5 **Total Wrist Replacement Arthroplasty Using a Surface Replacement Prosthesis/uHead Arthroplasty**  
William Cooney, MD  
Sponsored by Small Bone Innovations

BW 1 **Hand and Wrist Trauma Utilizing the Wrist F.I.T. Plating System and the New Modular Universal Hand System**

William Seitz, MD

Sponsored by Small Bone Innovations

6:00–7:00pm **Welcome Reception**

### AAHS

Thursday, January 12, 2006

- 6:30–8:30am Continental Breakfast
- 7:00–8:00am **Instructional Courses**
- 101 **Flexor Tendon Injuries**  
Michael Neumeister, MD, Moderator  
James Creighton, Jr, MD  
Rebecca von der Heyde, MS, OTR/L, CHT
- 102 **Hand Fractures**  
Matt Tomaino, MD, Moderator  
Robert J. Goitz, MD  
Sue Micholovitz, PhD, PT
- 103 **Stages and Treatment of Thumb Basal Joint Arthritis**  
Miguel Saldana, MD, Moderator  
Alejandro Badia, MD  
Paul Brach, MS, PT, CHT  
Nash Naam, MD
- 104 **Pediatric Hand Injuries**  
Scott Kozin, MD, Moderator  
Benjamin Chang, MD  
Christine J. Cheng, MD
- 105 **Surgical Management of Dupuytren's**  
Michael Jabaley, MD, Moderator
- 8:00–9:00am **Panel – Challenging Wrist Pain**  
Mark Baratz, MD, Moderator  
Brian Adams, MD  
Mark Cohen, MD  
Steven Moran, MD  
Thomas Trumble, MD
- 9:00–10:00am **Panel – Challenging Nerve Cases**  
Allen Van Beek, Moderator  
Neil Ford Jones, MD  
Susan Mackinnon, MD  
Dean Sotereanos, MD  
Julia Terzis, MD
- 10:00–10:15am **Break**
- 10:15–11:00am **Keynote Speaker: Jeff Lichtman, MD, PhD**  
“Studying Axon Growth and Regeneration in Fluorescent Mice”

Hand Surgery  
Quarterly

.....  
Autumn  
2005

**11:00am – 12:00pm** **Distal Radius Fractures – Defend Your Plate**  
*Alan Freeland, Co-Moderator*  
*Jaiyoung Ryu, MD FACS, Co-Moderator*  
*Randy Bindra, MD*  
*William Geissler, MD*  
*Thomas R. Hunt, III, MD*  
*Jorge Orbay, MD*  
*Matthew Putnam, MD*

**12:00–12:15pm** **Box Lunch**

**12:15–1:45pm** **Concurrent Scientific Paper Session**

**12:15–1:45pm** **Concurrent Scientific Paper Session**

**12:15–6:05pm** **Comprehensive Review Course**  
 Course is complimentary, but pre-registration is required.

**12:15–12:30pm** **Tendonopathies and Dupuytren's Contracture**  
*Peter M. Murray, MD*

**12:30–12:50pm** **Compression Neuropathies**  
*Daniel Nagle, MD*

**12:50–1:00pm** **RSD**  
*Daniel Nagle, MD*

**1:00–1:15pm** **Degenerative Arthritis of the Hand and Wrist**  
*Matt Tomaino, MD*

**1:15–1:25pm** **Kienbocks**  
*Matt Tomaino, MD*

**1:25–1:45pm** **Inflammatory Arthritis of the Hand and Wrist**  
*Brian Adams, MD*

**1:45–1:50pm** **Questions**

**1:50–2:10pm** **Distal Radius Fractures**  
*Peter J. L. Jebson, MD*

**2:10–2:25pm** **The Distal Radio-Ulnar Joint**  
*Brian Adams, MD*

**2:25–2:35pm** **Scaphoid Fractures and Non-unions**  
*Peter J. L. Jebson, MD*

**2:35–2:55pm** **Wrist Dislocations and Instabilities**  
*Richard Berger, MD, PhD*

**2:55–3:10pm** **Metacarpal and Phalangeal Fractures**  
*Stephen D. Trigg, MD*

**3:10–3:15pm** **Questions**

**3:15–3:30pm** **Extensor Tendon Injuries**  
*Kevin Renfree, MD*

**3:30–3:50pm** **Flexor Tendon Injuries**  
*Kevin Renfree, MD*

**3:50–4:05pm** **Infections of the Hand**  
*Kevin Planchar, MD*

**4:05–4:25pm** **Congenital Hand Anomalies**  
*Scott Kozin, MD*

**4:25–4:45pm** **Tumors of the Hand and Wrist**  
*Edward A. Athanasian, MD*

**4:45–4:50pm** **Questions**

**4:50–5:10pm** **Peripheral Nerve Injury and Reconstruction**  
*Michael B. Wood, MD*

**5:10–5:25pm** **Tendon Transfers**  
*Michael B. Wood, MD*

**5:25–5:45pm** **Soft Tissue Coverage of the Hand**  
*William C. Pederson, MD*

**5:45–6:00pm** **Vascular Disorders of the Hand/ Replantation**  
*Peter M. Murray, MD*

**6:00–6:05pm** **Questions/Adjourn**

## AAHS Friday, January 13, 2006

**7:00–8:00am** **Annual Business Meeting Breakfast**

**7:00–8:00am** **Concurrent Instructional Course for Residents, Fellows & Non-members**

**106** **Getting Your Practice Started**  
*Jeffrey King, MD*  
*Steven Meletiou, MD*  
*Jose Ortiz, Jr., MD*

**107** **Money Management**  
*Jeff Palmer, Smith Barney*

**8:00am – 4:00pm** **Computerized Instructional Courses**

**8:00–9:00am** **Board of Directors Meeting**

**8:00–9:00am** **Instructional Courses**

**108** **Nerve Gap**  
*Dimitri Anastakis, MD, Moderator*  
*Linda Dvali, MD*  
*Terry Myckatyn, MD*

**109** **Adult and Pediatric Elbow Trauma**  
*Mark Baratz, MD, Moderator*  
*Mark Cohen, MD*  
*Judy Glas, OT*  
*Scott Kozin, MD*

**110** **Recognition and Management of Carpal Instabilities**  
*Steven Moran, MD, Moderator*  
*Paul Lastayo, PhD, PT, CHT*  
*Marco Rizzo, MD*

**111** **Extensor Tendon Repair & Management – Immediate Active Motion**  
*Wyndell Merritt MD, Moderator*  
*Julianne Howell, PT, MS, CHT*

**112** **Hand Surgery and Therapy Missions in Developing Countries – Pearls & Pitfalls**  
*Warren Schubert, MD, Moderator*  
*Lynn Bassini, OTR, CHT*  
*Miguel Pirela-Cruz, MD*

**9:00–10:00am** **Panel - Challenges of Hand Trauma**  
*Nicholas Vedder, MD, FACS, Moderator*  
*Allen Bishop, MD*  
*Richard Brown, MD*  
*A. Lee Osterman, MD, FACS*  
*Thomas Trumble, MD*

**10:00–10:45am** **Break with Exhibitors**

**10:45–10:55am** **ASSH Presidential Welcome**  
*David M. Lichtman, MD*

**10:55–11:15am** **AAHS Presidential Address**  
*Susan Mackinnon, MD*

**11:15am – 12:00pm** **Joseph Danyo Presidential Invited Lecturer: Peter Amadio, MD**

“Three Decades of Tendon Research: The Search for the Perfect Slide”

**12:00–12:15pm** **Break**

**12:15–2:00pm** **Concurrent Scientific Paper Sessions**

**2:00–3:30pm** **Panel - Operative Pearls from My Surgical Practice**  
*Susan Mackinnon, MD, Moderator*  
*Peter Amadio, MD*  
*Richard A. Berger, MD, PhD*  
*A. Lee Osterman, MD, FACS*  
*Robert Russell, MD*  
*Nicholas Vedder, MD, FACS*

**5:30–7:00pm** **AAHS Silent Auction and Reception Benefiting HSE**

Hand Surgery Endowment (HSE)  
*Alan Freeland, MD*

Presentation of Awards

Posch Award for Resident/Fellow Research Paper

Research Grant Award

*continued on page 8*

continued from page 7

## AAHS/ASRM/ASPN

Saturday, January 14, 2006

- 6:00–8:00am Continental Breakfast
- 6:30–7:30am Instructional Courses
- 201 Indications, Timing and Interpretation of Electrophysiology  
*Harvey Goodman, MD  
Allen Van Beek, MD*
- 202 Interdisciplinary Management of Pain  
*A. Lee Dellon, MD  
Randall Prust, MD*
- 203 Nerve Transfers  
*Susan Mackinnon, MD  
Christine Novak, PT/MS  
Renata Weber, MD*
- 204 Outcome Measures: Quality of Life  
*Kevin Chung, MD  
Brent Graham, MD  
Steven McCabe, MD  
Achilleas Thoma, MD, FRCSC*
- 205 Reinnervating Muscle  
*Paul Cederna, MD, FACS  
Nancy McKee, MD, FRCSC*
- 7:45–7:55am **Presidents' Welcome**  
*Susan Mackinnon, MD, AAHS President  
Maria Siemionow, MD, PhD, ASPN President  
William C. Pederson, MD, ASRM President*
- 7:55–8:00am **ASPS Presidential Remarks**  
*Scott Spear, MD, ASPS President*
- 8:00–9:30am **Panel: Composite Tissue Allografts**  
*William C. Pederson, MD, Moderator  
W. P. Andrew Lee, MD  
Mary McGrath, MD  
Susan Mackinnon, MD  
Maria Siemionow, MD, PhD*
- 9:35–10:35am **AAHS/ASRM/ASPN Presidents Invited Lecture: Colonel Mark Bagg, MD**  
*"War and Disaster Injuries"*
- 10:35–11:00am Coffee/Exhibits Break
- 11:00–11:45am Outstanding Nerve Paper Presentations
- 12:30pm **10th Annual Day at the Links**
- 6:00–6:45pm **AAHS/ASRM/ASPN Reception with Exhibitors**
- 6:45–9:00pm **Off-Property Western Dinner**

## AAHS

Saturday, January 14, 2006

AAHS Hand Therapy Program

12:00pm–5:00pm

**The Challenge: Hand Surgeons and Therapists—What Evidence Do You Have to Do That?**

**Carpal Tunnel Syndrome, DeQuervain's and Trigger Finger**

*Peter Amadio, MD  
Sue Michelovitz, PhD, PT, CHT  
Mark Walsh, PT, MS, CHT  
Sandy Robinson, OTR, CHT  
Julianne Howell, PT, MS, CHT*

**Point-Counterpoint:**


*Wyndell Merritt, MD, FACS  
Jane Fedorczyk, MS, PT, ATC, CHT  
Gail Groth, OTR/L, CHT, MHS  
Chris Novak, PT, MS*

**The Ultimate Challenge: Gathering the Evidence Base—Can We Get Hand Surgeons and Hand Therapists to Collaborate?**

*Joy MacDermid, BScPT, PhD*

**Metacarpal and Phalangeal Fractures**

*Lynne Feehan, PT, CHT  
Maureen Hardy, PT, MS, CHT  
Alan Freeland, MD  
Jaiyoung Ryu, MD, FACS*

**Question & Answer** 



**Make a donation.  
Win a vacation.**

The Hand Surgery Endowment supports the educational, research, humanitarian and membership outreach efforts of the AAHS. We'll be conducting a silent auction at the AAHS Annual Meeting next January to raise money for this important AAHS subsidiary, and we need your help. If you have an item you can donate for the silent auction, please complete the donor form and submit it before September 26, 2005.

Two lucky donors will win a two night stay at the Ritz-Carlton Cancun, a five diamond resort located on the tip of the exotic Yucatan peninsula. Winners will be selected during a drawing at the event. And every donor that submits their form before the deadline will receive a special mention in the Auction Program Guide, distributed to every registered attendee at the AAHS 2006 Annual Meeting.

Help us keep the Hand Surgery Endowment vital by contributing a silent auction item today. Who knows - it could be the most rewarding donation you've ever made.

## LEADERSHIP PROFILE

### Junior Director at Large George H. Landis, MD

**D**r. George H. Landis is a newly elected board member of the AAHS. George first presented to the Association at the 28th Annual Meeting in 1998 in Phoenix. He says his original interest in AAHS was the wonderful warm-weather annual meeting sites that brought him in from the frigid Minnesota winters. George has since found the association a terrific combination of excellence in education, high levels of professionalism, and a friendly inviting community.

Born in Cleveland, Ohio, George grew up in San Diego, California. In 1988 he moved out to Minneapolis to begin his surgical internship at the University of Minnesota and completed his plastic surgery residency there in 1994. He remained at the UM for eight years practicing reconstructive plastic surgery. George developed an interest in surgical education as residency director for the 24 surgical interns at the University of Minnesota and in the training of plastic surgery residents during his time at the UM.

In 2002 he left the University for a solo plastic surgery practice where he revived his hand surgery skills at North Memorial Medical Center where Allen Van Beek had organized a regional hand trauma center. He now has a practice mix of cosmetic, reconstructive, and hand surgery.

As a self-proclaimed computer geek, George has dabbled in computers since the birth of the internet. At the University of Minnesota he implemented a web-based surgical residency evaluation system that has since been used in 1,500 medical residency and medical school programs. It is this interest

in the intersection of surgical education and computer technology that George brought to the association in 2004 with the introduction of the computerized instructional courses at the annual meeting in Palm Springs. The courses are expected to continue into the 2006 annual meeting in Tucson.

George has kept his interest in education and computers active in the American Society of Plastic Surgeons serving as chairman of the E-Learning Committee and as a member of the Web Editorial committee and the Education Technology committee.

George's true passion lies at

home with his wife, Karen, and his two children, Anna Marie (11) and Christopher (9). Between work and computers, George coaches Little League, basketball, volleyball, and is a Cub Scout Den Leader. His other interests include squash, skiing, fishing, and producing home videos and slide shows DVD. The family can be seen together at most AAHS meetings. **H**



## AAHS NEW MEMBERS / JULY 2005

### Active Applicants

Taizoon Baxamusa, MD  
*Morton Grove, IL*

Timothy Best, MD, MSc, FRCSC  
*Sault Ste Marie, ON*

James Boler, MD  
*Des Moines, IA*

Jerome Chao, MD  
*Albany, NY*

Scott Duncan, MD, MPH  
*Phoenix, AZ*

Peter Evans, MD  
*Cleveland, OH*

Robert Goitz, MD  
*Pittsburgh, PA*

Donald Lalonde, BSc, MSc, MD, FRCSC  
*Saint John, NB*

Subhash Patel, MD, FACS, FICS  
*West Columbia, SC*

Jeffrey Rodgers, MD  
*West Des Moines, IA*

Andreas Sauerbrey, MD  
*Steamboat Springs, CO*

Raj Sinha, MD  
*Springfield, IL*

Lester Yen, MD  
*West Des Moines, IA*

Han-Liang Yu, MD  
*Bronx, NY*

### Affiliate Applicants

Lisa Barry, MA, OTR/L  
*West Hills, CA*

Donna Breger Stanton, MA, OTR/L, CHT, FAOTA  
*Oakland, CA*

Micheline Craft-Maynor, OTR/L, CHT  
*Thousand Oaks, CA*

Coleen Gately, MSPT  
*New York, NY*

Sonja Kranz, OT  
*Rochester, MN*

Roberta Morris, OTR  
*Exton, PA*

Ann Porretto-Loehrke, PT, CHT, COMT  
*Appleton, WI*

### Candidate Applicants

Anureet Bajaj, MD  
*Cincinnati, OH*

Stephen Hankins, MD  
*King of Prussia, PA*

Hany Tadros, MD  
*Morgantown, WI*

Gregg Vagner, MD  
*Austin, TX*

Hand Surgery  
Quarterly

.....  
Autumn  
2005

# Health Volunteers Overseas: Improving Global Health Through Education

## HVO: A CASE FOR SPONSORSHIP

### The Background

Leading American professional health care associations play a prominent role in Health Volunteers Overseas (HVO). Over the past 19 years, HVO has developed a reputation for designing strong, effective clinical education programs in developing countries that successfully utilize short-term volunteers. The purpose of these programs is to train and support local health care professionals, giving them the knowledge and skills that will enable them to provide better care within their community. This emphasis on training and education is an excellent match with the mission of associations such as the American Academy of Orthopaedic Surgeons, the American Dental Association and other HVO sponsors. In addition, HVO programs also foster the development of professional networks, providing opportunities for health care professionals around the world to interact on national, regional and international levels. This too is consistent with the overall mission of the professional associations that sponsor HVO.

Health care associations often find that a segment of their membership is interested in international activities. Meeting this need with meaningful programming, therefore, is a challenge that many associations must address. While many

## AAHS To Sponsor Health Volunteer Overseas

Scott H. Kozin, MD

### What is Health Volunteer Overseas (HVO)?

- HVO is the leading non-profit organization that provides hands-on, volunteer-driven clinical education programs in developing countries
  - HVO has 57 programs in 25 developing nations
  - Orthopaedic and Hand Surgery Overseas are part of HVO. Since 2000, HVO has placed 103 hand surgeons as volunteers in developing countries
- At the mid-year meeting, the board unanimously approved sponsorship of HVO.

### Benefits to AAHS members include:

- Volunteer opportunities are readily available to AAHS members interested in international activities
- HVO will provide AAHS volunteers with extensive information about their professional role at the site and information about critical matters such as personal safety, housing, and travel
- Volunteer efforts by our members will be featured in the *Hand Surgery Quarterly*

### Benefits to AAHS include:

- AAHS will be listed as a sponsor on the HVO web site with a hyperlink to our website
- AAHS will be listed in the semi-annual newsletter, the annual report and on other printed materials
- AAHS will receive recognition for commitment to improving global health and will broaden our international relationships

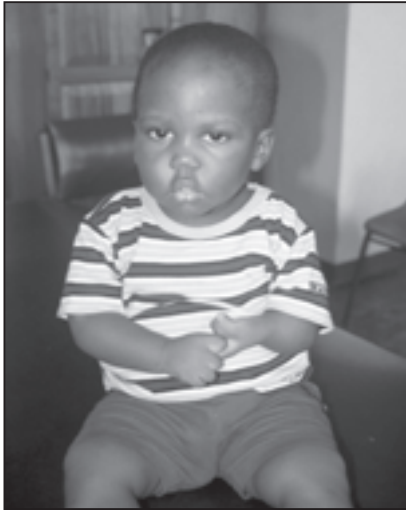If you are interested in volunteering, please contact HVO at [www.hvousing.org](http://www.hvousing.org) or 202-296-0928.

individuals are able to find opportunities through local churches and civic associations that utilize their clinical skills, these placements are very often dependent on the energy and commitment of one individual and his/her personal contacts. Hence these are often ad hoc arrangements that do not have long-term sustainable outcomes.

By linking with Health Volunteers Overseas, however, sponsors have the opportunity to be part of an ongoing and dynamic organization that has institutional partnerships with a wide variety of non-governmental organizations, government ministries and teaching institutions around the world. These partnerships are the result of years of relationship-building and provide HVO with the opportunity

to develop and sustain its educational programs. HVO programs are focused on strengthening the capacity of the health care infrastructure in developing countries; a long-term goal that addresses the human resource problem that has existed for many years but that has taken on a new urgency recently with the devastating impact of HIV-AIDS and the intense focus created by the Millennium Development Goals.<sup>1</sup>

HVO also has developed an excellent reputation for its volunteer management capability. Volunteers are provided with extensive information not only about their professional role at the site, but also about critical matters such as personal safety, housing, travel and other logistical matters.



For individuals without prior international experience this information and support is critical to their ability to plan their trip and prepare themselves properly for the experience. HVO has developed an assortment of background and orientation materials that introduce volunteers to a variety of topics that enable them to develop realistic expectations, which are so critical to a successful assignment.

Today, HVO has a broad array of sponsors, all nationally recognized professional societies. This sponsorship of HVO enables the association to address a member need, as well as providing the association with visibility both nationally and internationally on a critical issue on the global stage. The crisis in the health care workforce in developing countries has taken on an urgency and visibility today in light of the global commitment to eradicate poverty and improve the quality of life for millions of people around the world. HVO has quietly and methodically been addressing this crisis long before it took on the high profile it has today.

### Becoming a Sponsor

Sponsors are asked to contribute to HVO in two significant ways – financial and publicity. Annual dues for sponsors are \$4,000. All sponsors are listed on the HVO web site with a hyperlink, in the semi-annual newsletter, the annual report and on other printed materi-

als. Sponsors are also asked to provide free exhibit space at their annual or regional meetings and to feature stories about volunteer opportunities as well as stories from returned volunteers. Sponsors are also asked to create a link from their web site to HVO's site.

### Current Sponsors

American Academy of Dermatology  
American Academy of Orthopaedic Surgeons  
American Academy of Pediatrics  
American Association of Colleges of Nursing  
American Association of Oral and Maxillofacial Surgeons  
American Burn Association  
American College of Physicians  
American Dental Association  
American Orthopaedic Foot and Ankle Society  
American Physical Therapy Association  
American Society for Dermatologic Surgery

American Society for Surgery of the Hand  
Association of Bone and Joint Surgeons  
Scoliosis Research Society

### For More Information

For more information on becoming a sponsor, please contact Nancy Kelly, MHS, Executive Director at 202-296-0928 or [n.kelly@hvousa.org](mailto:n.kelly@hvousa.org). For more information on HVO's programs and other activities, please visit our web site at [www.hvousa.org](http://www.hvousa.org). **H**

- 1 The Millennium Development Goals (MDGs) grew out of a meeting in 2000 of world leaders at which a commitment was made to eradicate poverty, promote human dignity and equality and achieve peace, democracy, and environmental sustainability. Eight goals, three of which are specifically health-related, were selected and world leaders have promised to work towards these goals by 2015.

## VIEWING OPPORTUNITY

### WOUNDED IN ACTION comes to PBS!

The *Legacy of Heroes* program is a celebration honoring the heroism, dedication and sacrifices of the 600,000 military medical men and women who served in WWII, and highlights the contributions orthopaedic surgeons have made to advancements in care for trauma-related injuries. Over the next several months, PBS will be airing the documentary film developed as part of this initiative, *Wounded in Action*, which is a moving testimonial to our veterans' involvement in the Second World War. The film features some of our WWII veteran Academy members, taken back to the beaches at Normandy and Pearl Harbor where they served, to reflect on both tragic memories, heroic moments, and the impact these experiences had on their lives. A tentative schedule for public television stations across the country is available at <http://legacyofheroes.aaos.org>, and is updated weekly, but be sure to check your local PBS listings for confirmed airings. *Wounded in Action* on PBS has been made possible through educational grants provided by Pfizer, Inc., and the George M. Boswell, Jr., MD Fund for Orthopaedic Surgery, of the Wichita Falls Area Community Foundation. If you have any questions, please contact Addy M. Kujawa, [kujawa@aaos.org](mailto:kujawa@aaos.org) <<mailto:kujawa@aaos.org>>, 847-384-4033. Copies of the *Legacy of Heroes* book and *Wounded in Action* DVD are also available through AAOS Customer Service at 800-626-6726. **H**

Hand Surgery  
Quarterly

.....

Autumn  
2005

# Fractures of the Proximal Phalanx

For this discussion, we enlisted the moderating skills of **Alan Freeland, MD**, Professor Emeritus, Department of Orthopaedic Surgery and Rehabilitation, University of Mississippi Medical Center, Jackson, MS. Joining him in the discussion are hand surgeons **Alejandro Badia, MD, FACS**, Miami Hand Center, Miami, FL; **Amit Gupta, MD**, Department of Orthopedics, University of Louisville, Louisville, KY; and **Stephen Trigg, MD**, Assistant Professor in Hand Surgery and Orthopedics, Mayo Clinic, Jacksonville, FL. Providing perspective from the therapist quarter is hand therapist **Maureen Hardy, PT, MS, CHT**, St. Dominic Jackson Memorial Hospital, Hand Management Center, Jackson, MS.



**ALTHOUGH A PERFECT REDUCTION IS THE IDEAL, PROXIMAL PHALANGES OF THE FINGERS HAVE SOME TOLERANCE OF MILD DEFORMITY WITHOUT MANIFESTING SIGNIFICANT FUNCTIONAL DEFICIT.**

**ALAN FREELAND, MD**

**Dr. Freeland:** Scar tissue is the nemesis of the hand surgeon. This is particularly true of phalangeal fractures of the fingers secondary to the fibroblastic response generated by the periosteum and surrounding collagenous structures. Even sharp, low energy incisions and approaches add risk of scarring and stiffness to an already traumatized finger. Hand surgeons have long recognized the benefits of minimally invasive surgery, yet in certain circum-

stances open procedures remain necessary and sometimes preferable. We will discuss a variety of closed and open extra-articular fractures of the proximal phalanges of the fingers, showing how to achieve the goals of anatomic restoration, fracture stability and healing, and functional recovery while minimizing additional surgical trauma.

A high percent of closed, simple, transverse or slightly oblique proximal phalangeal fractures of the fingers are nondisplaced or minimally displaced and stable. How would you treat these fractures?

**Dr. Badia:** It depends upon the fracture pattern. I increasingly try to use less invasive approaches. I utilize minimal fixation if possible and

neutralize the role of the intrinsics by flexing the MP joints. If the fracture appears relatively stable in that position, I try to avoid fixation. If stabilization is necessary, I try to use intermedullary pinning, reducing the proximal phalanx into an acceptable position and then rely upon the adjacent fingers to help keep the finger in the correct alignment. Dorsal MP blocking, then, allows protected early motion.

**Dr. Freeland:** Dr. Trigg, do you have any additional comments?

**Dr. Trigg:** No, that's basically my approach. If pin fixation becomes necessary, it is minimal. I rely on dorsal extension block splinting for the stable fracture that I am not going to fix and adjacent buddy taping. I think determining initial stability is the key.

**Dr. Freeland:** Do any of you treat these fractures without protection? For example, an impacted transverse extraarticular fracture at the base of the proximal phalanx?

**Dr. Gupta:** I always used some sort of protection. I know the maximum impact or deformity occurs at the time of the injury, but I always advise some sort of protection because I'm not sure how patients will use their hands. In using buddy taping with minimally displaced fractures, you can get a pseudo correction. I check them pretty much every week to make sure that I'm not spuriously correcting the deviation or deformity.

**Dr. Freeland:** Although a perfect reduction is the ideal, proximal

phalanges of the fingers have some tolerance of mild deformity without manifesting significant functional deficit. How much deformity is allowable in terms of shortening, angulation and rotation?

**Dr. Gupta:** Well, certainly the thumb is able to tolerate quite a bit of rotation and deviation. In the digits, especially the proximal phalanx, rotation is not tolerated. A slight bit of displacement in the coronal plane, even up to a third, is tolerated as long as the relationship to the other digits is maintained. However, rotation, deviation and angular deformities are poorly tolerated. I would not accept anything more than 5 degrees of deviation.

**Dr. Freeland:** Ms. Hardy, tell us about static and functional splints for closed stable transverse and slightly oblique extraarticular proximal phalangeal fractures.

**Ms. Hardy:** Certainly, but first I'd like to mention a little bit about the soft tissue defects that can occur with P1 deformity. We know that for every 1mm of shortening or angulation of P1 you get a 12 degree extensor lag at the PIP joint (Vahey JHS 1998). And we also know that the interossei muscles are affected by bone shortening in that they have a functional slackening of normal tension and lose power (Meunier JHS 2004). P1 deformities not only affect the architect of the digit, they also affect the soft tissues around the bones.

**Dr. Badia:** I'd like to comment on that. I think we all agree that spiral

fractures have obvious problems with rotation. The more common fracture is volar-apex angulated and less well tolerated as you go to the ulnar side. I pay particular attention to this fracture in younger, active people who need to make a tight strong fist. I think you have to obtain a good reduction so that they do not lose flexion and, subsequently, power.

**Dr. Gupta:** Moreover, with volar angulated fractures, you can get a secondary deformity of the PIP joints. The initial extension deficit at the PIP joint due to the volar angulated fracture of the proximal phalanx can eventually result in a flexion contracture of the PIP joint.

**Dr. Freeland:** There may be as great as 2mm to 6mm of viscoelastic compensation of the extensor mechanism prior to the onset of extensor lag at the proximal interphalangeal joint owing to relative bone to extensor tendon length discrepancy caused by volar angulation. More than 15 degrees of volar angulation may not only initiate extensor lag at the proximal interphalangeal joint, but also affect the gliding mechanism and dynamics of the extrinsic flexor tendons.

Ms. Hardy, continue please.

**Ms. Hardy:** Static, radial or ulnar gutter splints, may be used initially. These same border splints can convert to functional splinting through the concept of serial reduction. Colditz (*Rehabilitation of the Hand*, 1995) and Feehan (*JHT* 2003) both champion their idea in which proximal and distal joints are freed as healing ensues, thus permitting gradually more functional mobility.

In addition, using C-arm visualization is it possible to know if full active range of motion can occur without loss of stability; or, is there a certain limited safe range? If so, then these fractures can be managed with protective immobilization that maintains the reduction but restricts motion in the direction of instability.

**Dr. Freeland:** When do you perform closed reduction and percutaneous internal fixation with Kirschner

wires and when do you open these transverse or slightly oblique fractures?

**Dr. Trigg:** If you can perform a satisfactory reduction with a short oblique or transverse fracture and convert it to a stable fracture with the patient actively flexing or looking at it under the C-arm, then I think I might give it a go. If there were any question, then I would certainly put in some sort of internal fixation, usually a K wire.

**Dr. Freeland:** Do you insert inter-medullary Kirschner wires from the side of the phalanx proximally or do you go through the metacarpal head?

**Dr. Trigg:** I think that I was initially resistant going through the metacarpal head, but I find that approach to be a very safe and reliable method. If I feel the stability is good, then I have used both methods with equal success. It just seems that the trans-articular approach through the head is very safe and yields very good results provided you have a reliable patient.

**Dr. Freeland:** Transverse and mildly oblique fractures become progressively more unstable the more distally that they occur. Do you have any special recommendations for treating these fractures when they occur in the middle and distal thirds of the proximal phalanx?

**Dr. Badia:** Well again, I try to use an intra-medullary rod by entering the flare at the base of P1. If it is quite distal, then I often insert two of them trying to have each engage a condyle to provide additional stability. I pay more attention to protecting the PIP joint with some type of splint where we try to keep the PIP joint in extension, avoiding flexor contraction, while at the same time providing more stability to the fracture.

**Dr. Freeland:** Do you ever use a locking pin in the proximal phalanx?

**Dr. Badia:** I have, but I've done that more in the metacarpals. If I feel it is that unstable, sometimes I will

actually add a separate K wire entering distally as a sort of a derotational K wire and then cut it just underneath the skin.

**Dr. Freeland:** When do you open a transverse or moderately oblique fracture?

**Dr. Gupta:** I try to reduce these closed under local anesthetic. These short oblique fractures are generally quite unstable and I try, if I can, to get a K wire down the medullary canal as Dr. Badia has described, engaging the distal part. If I'm not satisfied and it seems that I'm not getting a good reduction, then I don't have any hesitation opening the short oblique fractures and fixing them internally. I try to put the plate and screws on the side of the bone in the proximal phalanges.

**Dr. Freeland:** Once you open the fractures, do you still use Kirschner wires or do you ever use mini plates or screws?

**Dr. Gupta:** I never use an unstable construct if I open a fracture.

**Dr. Freeland:** Any further comments on transverse or mildly oblique fractures of the proximal phalanx?

**Dr. Gupta:** Other options include types of fixation, like tension band wiring or Belsole-type wiring, which are minimally invasive and yet provide very stable fixation.

**Dr. Freeland:** Does anybody use mini-external fixators?

**Dr. Gupta:** I don't.

**Dr. Trigg:** No.

**Dr. Badia:** Not in that scenario.

**Dr. Freeland:** I haven't either. Well, very rarely. Let us move on to long oblique fractures of the proximal

*continued on page 14*



**I INCREASINGLY TRY TO USE LESS INVASIVE APPROACHES. I UTILIZE MINIMAL FIXATION IF POSSIBLE AND NEUTRALIZE THE ROLE OF THE INTRINSICS BY FLEXING THE MP JOINTS.**

**ALEJANDRO BADIA, MD, FACS**

Hand Surgery  
Quarterly

.....

Autumn  
2005

13

## AROUND THE TABLE

continued from page 13

phalanx. How do you treat a closed non-displaced or minimally displaced long oblique fracture? Dr. Trigg?

**Dr. Trigg:** I don't see them as often as I would like. If one of the cortices

remains (fractured but non-displaced), and you can establish that the fracture is stable, then I think, try closed treatment. However, in the majority of cases, long oblique fractures are unstable and shortened with rotation. I've had very good luck with closed reduction and fluoroscopy using percutaneous K wires and a bone reduction clamp.

**Dr. Freeland:** Does anybody open these? Dr. Badia?

**Dr. Badia:** I generally don't in this situation but I have used a percutaneous screw technique where I ensure that the reduction is good and then

the screw just gives you a little bit of added insurance. I do not have to open it, as I would a long spiral fracture, to obtain a good reduction. I make small stab incisions in two slightly different planes and then once I put those screws in, I can begin early motion in a removable MP block type splint. They can remove that at home and just do gentle range of motion.

**Dr. Gupta:** I have a comment. I think it is very important to get these properly reduced because in trying to derotate the fracture and buddy splint it to the neighboring digit, you can get a spurious reduction. Then you have malrotation when it heals. Therefore, I think it is very important to get a good reduction

and then provide some form of fixation, like percutaneous K wires or screws, as mentioned.

**Dr. Freeland:** How do you manage spiral fractures?

**Dr. Badia:** I do a mid-axial incision. I try to sneak under the lateral bands and elevate the extensor mechanism as a unit. Then, I look for the extreme ends of the fracture, reducing the point, then see what it looks like rotationally. I try to use a series of screws that are rotating around the proximal phalanx trying to avoid plates at all costs if I can. I will place two screws and then I will look at the hand clinically, evaluating the rotation by flexing the MP joints. If I'm happy with the appearance and the fluoro image looks good, then I'll just make sure I have enough screws for adequate stability. If I am concerned about the lateral band impinging then I will sometimes do a Littler-like incision, removing a small triangular portion of the band.

**Dr. Freeland:** I'd like to point out that percutaneous fixation of displaced long oblique fractures of the proximal phalanx is not an easy procedure. The cortex is hard. A fixation clamp or an assistant must hold the reduction. The surface of the sides of the phalanx is round and the K wire tends to skate unless stabilized. I've recently reviewed the literature and it is interesting to note that there is very little difference in outcome between percutaneous Kirschner wire fixation compared to open Kirschner wire or mini-screw stabilization of closed unstable long oblique extraarticular proximal phalangeal fractures.

**Dr. Gupta:** I would agree. Certainly, with the newer fracture clamps, like the Lalonde clamp, percutaneous fixation is easier to do. If there is any doubt, or difficulty with anatomically reducing or fixing the fracture, I have no hesitation opening the fracture and putting screws at 90 degrees to the fracture plane.

**Dr. Freeland:** What are the restrictions for fractures fixed with Kirschner wires? When you have screw fixation you feel confident

that everything is stable, but how do you handle fractures stabilized with Kirschner wires?

**Ms. Hardy:** Well there is a fear factor out there about performing any range of motion with wires or pins. When you look in the literature, you are warned about infection, pin migration, fracture displacement, and non-union in fractures managed with coaptive fixation; it is enough to scare any therapist or physician! Too often, I see therapists only concerned with designing a creative splint around the exposed wires, and nothing more. Therapy is delayed for 4 to 6 weeks until the pins are removed, which is too late for soft tissue integrity. However, maximal tissue movement is not necessary and sometimes it is not even possible with the pins in place, but short arc motion is possible and beneficial for the PIP joint. Motion from full extension 0 to 40 degrees for central slip excursion, and FDP/FDS differential glide of 5mm is enough to maintain those gliding planes and minimize the risk of adhesions.

We also know wrist extension decreases extension force at the proximal phalanx by one third, so do the opposite: flex the wrist when exercising to help assist PIP extension through passive tenodesis. One final point, doctors please inform the therapists when they're using buried K wires or pins in order to avoid the misconception that ORIF without exposed hardware means rigid implants were used. Better yet, send the OP report to the therapist.

**Dr. Freeland:** I believe that you're relatively safe with short-arc proximal phalangeal joint motion. This is the same motion and rationale we use to rehabilitate flexor tendon laceration repairs in Zone 2. If we can regain 40 degrees of proximal interphalangeal joint motion in the first 4 weeks after injury, our chances of having good to excellent final recovery of digital motion should be high. I would reemphasize the importance of communicating with the therapist regarding the type and security of the fixation.



I LIKE TO  
USE CONDYLAR  
PLATES FOR  
RECONSTRUCTION OF  
INTRAARTICULAR  
FRACTURES AND IN  
RECONSTRUCTION OF  
SEGMENTAL DEFECTS.

AMIT GUPTA, MD

Is there anything else you need to know from a therapy standpoint?

**Ms. Hardy:** Yes, I need to know three things. One, always tell me the date of injury and/or surgery because this starts the fracture healing timetable which drives the therapy progression. Two, what is the method of fixation you used; tell me the exact type of implant for each fracture, especially in hands with multiple fractures. Finally, when you dictate your clinic notes, or your operative or ER notes, copy the therapist so they can have the details of the fracture management.

**Dr. Gupta:** One more thing the physiotherapist needs to know is how confident the surgeon is in the fixation. The mere appearance of a screw on the x-ray does not mean it is a stable fixation. Only the surgeon knows how stable the construct is.

**Dr. Freeland:** I have heard a lot recently about tissue response mediated, unresisted active range of motion exercises. Can you tell us when and how to initiate exercises and at what point the fracture is stable enough to advance to more intensive and frequent active range of motion exercises, as well as starting strengthening and returning to activities?

**Ms. Hardy:** There are two timelines based on fracture healing. For fractures healing with secondary callous formation, we need to protect the callous healing for up to—but not beyond—3 weeks, followed by controlled mobilization of the soft tissues around the fracture until about 6 to 8 weeks, when strengthening exercises can begin. Return to unrestricted work or sports in the dominant hand really needs to wait until after this point.

With rigid forms of fixation that allow the fracture to heal by direct union, we can, should and must mobilize the soft tissues after the first week of inflammation subsides. The goal is to achieve full passive and active tissue mobilization during the next two weeks. In the direct union timeline, strengthening exercises must wait 6 to 8

weeks, similar to callous healing, because the fracture under the implant has to remodel and regain its own tensile strength independent from the hardware.

**Dr. Freeland:** The appearance of callous on x-ray usually lags the resolution of swelling and tenderness and the appearance of clinical stability. Once you see callous on x-ray then the fracture is “locked” and you can advance and intensify therapy with vigor knowing you are safe.

Have you ever used straight or mini-condylar plates for proximal phalangeal fractures? If so, what are the indications, advantages and disadvantages of mini-plate fixation?

**Dr. Trigg:** I rarely use the mini-condylar plates. However, I think the most common indication for their use is comminuted neck fractures with an unstable P1 head. As far as mini-plates for other types of fractures, I try not to use them. I think some sort of intermedullary or interosseous wiring is probably preferable to the plate fixation. Given the bending forces on some of these smaller plates (unless you have quite a number of screws and therefore more exposure with more of a chance of adhesions) these plates are unwarranted except in exceptional circumstances.

**Dr. Freeland:** Do you put the mini-condylar plates on dorsally or laterally?

**Dr. Trigg:** I try to put them on laterally when possible.

**Dr. Freeland:** Do you incise and repair the lateral band or do you excise it?

**Dr. Trigg:** I try to elevate the distal dorsal lateral band, which I think is preferable to excising it. However, in some of the more difficult fractures, it is necessary to use the so-called Littler technique where a small triangular portion of the distal lateral band is excised on one side. Finally, in many cases, there is significant maceration of the tissues in the more commuted fractures so excising a portion of it is usually

not detrimental to the patient’s outcome.

**Dr. Freeland:** Dr. Badia, any comments on mini-plate fixation?

**Dr. Badia:** I have only used them when there is some type of segmental defect, such as in penetrating trauma, where you need more stability, and where you may bone graft or something of that nature. With the other fractures we are discussing, I rarely use a plate.

**Dr. Freeland:** So you may use them for open or comminuted fractures and/or fractures with segmental bone loss?

**Dr. Badia:** Yes, and sometimes for non-unions/malunions where I can dial in the rotation correction and then lock the plate in more proximally once I’ve gained control of the condyles.

**Dr. Freeland:** I presume you would use a dorsal approach for mid-shaft fractures or defects?

**Dr. Badia:** I still try to go on the lateral side because I like to be able to elevate the extensor mechanism as a unit. I don’t see a problem with that approach. I try to minimize any problems with the extensor mechanism directly on the plate.

**Dr. Freeland:** Dr. Gupta, I know that you’re doing primary fixation and bone grafting for open fractures with defects.

**Dr. Gupta:** Yes.

**Dr. Freeland:** Do you use a dorsal approach or a lateral approach or does it depend on the site and configuration of the wound and the fracture?



**I DEFINITELY  
INCREASE MY USE OF  
INTERNAL FIXATION  
[WHEN THERE ARE  
MULTIPLE  
FRACTURES].**

**STEPHEN TRIGG, MD**

## AROUND THE TABLE

continued from page 15

**Dr. Gupta:** Generally, it depends on the fracture but I try very hard to place the plates and work on the lateral side of the digit as much as possible. I do use condylar plates especially for high-energy fractures, particularly the comminuted fractures.



**WE ALSO KNOW WRIST EXTENSION DECREASES EXTENSION FORCE AT THE PROXIMAL PHALANX BY ONE THIRD, SO DO THE OPPOSITE: FLEX THE WRIST WHEN EXERCISING TO HELP ASSIST PIP EXTENSION THROUGH PASSIVE TENODESIS.**

**MAUREEN HARDY, PT, MS, CHT**

I like to use condylar plates for reconstruction of intraarticular fractures and in reconstruction of segmental defects. I find them very useful. In addition, they are invaluable in the correction of malunions. Finally, in open fractures such as low velocity gunshot wounds, especially if I am replacing a segment and doing primary bone grafting, I need to get good stability.

**Dr. Freeland:** Are you using cancellous or corticocancellous bone for grafting?

**Dr. Gupta:** I used to use corticocancellous bone just like the exercise in the AO

hand course, keeping the cortical side of the graft opposite to the plate. More recently, I am using the compact cancellous graft. I first reconstruct the length and geometry of the fracture, and then I put the plate on and leave the gap filling it with a compact cancellous graft.

**Dr. Freeland:** Tell us about the compacted cancellous bone graft.

**Dr. Gupta:** I use a two or three milliliter syringe. First, I take out the plunger and fill the syringe with the cancellous graft. Next, I reinsert the plunger and squeeze the blood out, leaving the blood in another pot. Then I take the

plunger out and use a .45 K wire to push the graft out from the syringe. The tube of bone comes out as a very nice compact cancellous graft very similar to the shape of the defect in the phalanx. It fits very nicely and then I pour the blood back into the bone. That forms a very high concentration of bone cells and BMPs.

**Dr. Freeland:** What donor site are you using?

**Dr. Gupta:** I'm using the iliac crest. I just make a small little window and scoop out the cancellous bone.

**Dr. Freeland:** Do you use any substitute bone graft or synthetic bone graft?

**Dr. Gupta:** Not in those situations.

**Dr. Trigg:** I don't. I use crest, distal radius or ulna. In fractures with such little bone surface, I don't think I would use any of the synthetic bone substitutes.

**Dr. Freeland:** Dr. Badia, have you used any synthetic or substitute bone graft in the proximal phalanx?

**Dr. Badia:** On rare occasions, I have combined it when I needed more graft than I took from the distal radius. I try to avoid the iliac crest so I will use some of the coral type of graft and mix it in with the cancellous graft. It has worked fine on these rare occasions. It gives you a little opacity on the x-ray, which is a bit curious, but clinically the patients have done fine. It would be interesting to be able to go back in and look at that union histologically.

**Dr. Freeland:** At evidence level five, meaning I have done it in a few cases provided the major fracture fragments are in contact at some point and so far, I'm not aware of any problems although follow-up has been limited.

Dr. Gupta, I'd like to get back to you for a second. Since you are doing immediate fixation and bone grafting, I'd like to know whether a wound has to be clean? Are there any times that you do not do it and hold off? Also, how are your results so far?

**Dr. Gupta:** I think it is very important to take care of the soft tissues. I have a very low threshold for doing tissue substitution like local flaps. One of the worst things you can do when you do these complex reconstructions is to tightly close the wound or pull the tissues together and hope that the wound will heal. First, I try to do a very good debridement. Of course, I do not do complex one-stage reconstructions for patients who have had a farm injury or in very dirty wounds. Nevertheless, these reconstructions work well for things like low velocity gunshot wounds or in people who have had a saw injury, where a good debridement is feasible. The key is to get the soft tissue coverage as nicely as possible. I do local flaps in the proximal phalanges. I take some of the tissue from the dorsum of the hand, the small Quaba flap, based on a branch of the metacarpal artery, and just turn over the flap 90 degrees and cover the wound. As long as care is taken with the soft tissues, I think these procedures will work well.

**Dr. Freeland:** When there are multiple fractures in the same hand, are you using internal fixation? What are your alternatives?

**Dr. Trigg:** I definitely increase my use of internal fixation. Therefore, the hand is rehabilitated compositely rather than individually. Individualizing the therapy on each digit complicates it for the therapist and is a detriment to the outcome. I prefer stable internal fixation so that I can tell the therapist collectively what to do with the hand. I think this is the better way to go.

**Dr. Freeland:** Dr. Badia, any comments on severe or mutilating hand injuries?

**Dr. Badia:** In Miami, we don't have a lot of big industry like some of the other participants, so we don't tend to see a lot of this type of injury. What I do see occasionally are delayed problems from these injuries, sometimes from overseas. I think this is where your hand therapist is particularly crucial.

**Dr. Freeland:** Ms. Hardy, any special thoughts for the more severely injured hands?

**Ms. Hardy:** Yes, if you have a mixture of stable and non-stable fixation methods in the same hand you have to defer back to the least rigid method of fixation for managing that hand.

**Dr. Freeland:** So, fixing all of the fractures might provide an advantage in terms of how fast and how intensely you can proceed with therapy?

**Ms. Hardy:** That is correct. Otherwise, you have to manage it at the least level of stability rather than the greatest level. This implies that injury involving bone and soft tissues can progress more rapidly if rigid fixation is used. Rigid fixation allows safe, immediate mobilization of tendon, ligament and nerve associated injuries.

**Dr. Freeland:** If we are not getting motion back as quickly or to the extent that we should, at what point can we start passive stretch-

ing, dynamic splinting, and other modalities to try to prevent stiffness?

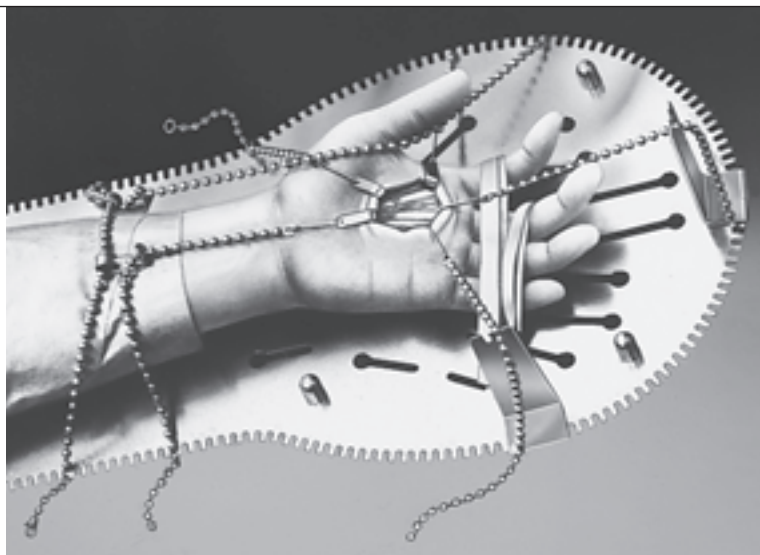
**Ms. Hardy:** I think prevention is the first aspect that needs reviewing. *The enemy of PIP joint mobility is MP joint hypermobility.* At the P1 level, 90% of the bone is covered by gliding tissues. In the worst-case scenario, tendon adhesions form in the central slip and in the FDP. Extensor lag becomes a fixed joint contracture at the PIP joint, and this is compensated by the MP joint hyperextending to clear the flexed finger from the palm. This is called a "pseudo claw deformity." To prevent this deformity, a day splint blocking and holding the MP joint in flexion will prevent the MP hyperextension, and directs all flexor and extensor power distally to the PIP joint. Hourly the patient is taught to perform isolated FDP, FDS and central slip gliding exercises; the latter is performed with the MP joint blocked in flexion. If patients have difficulty performing these tendon-gliding exercises, elec-

trical stimulation is used to contract the intrinsics (electrodes are placed on the palm and the dorsum of the hand) for PIP extension, or to the long flexors for fisting to achieve full motion. Always at night, we go back and rest the PIP joint in full extension in a static splint.

**Dr. Freeland:** When may patients resume activities of daily living, work, recreation, and other responsibilities?

**Ms. Hardy:** Hopefully, we have done everything correct and they're back to performing activities of daily living at 6 to 8 weeks. Work, requiring heavy hand use, as well as unrestricted sports activity, is usually delayed until 10 to 12 weeks. However, if they developed stiffness, our first goal is passive joint mobility. We must regain PROM with daytime, static progressive splints, such as a joint jack or turnbuckle splint; and night splinting with a turtle shell splint (a bivalve circumferential splint) that is adjusted into full extension as they

*continued on page 18*



**ASSI-TH100**

Adult Hand Table & Retractor Set includes TH-101 and TH-102 to TH-110 (Table and Retractor components)



**accurate surgical & scientific instruments corporation**  
300 Shames Drive, Westbury, NY 11590  
**800.645.3569 516.333.2570 fax: 516.997.4948**  
west coast: 800.255.9378 **www accuratesurgical.com**

## ASSI® Hand Tables and Retractor Sets

- Provides hand fixation in virtually any operating position.
- Facilitates a broader range of procedures single-handedly.
- Provides clear unobstructed access to the surgical site.

Hand Surgery  
Quarterly

.....

Autumn  
2005

© 2005 ASSI®

## AROUND THE TABLE

continued from page 17

improve with their daytime splint. We teach the patient to perform simultaneous heat and stretch at home three times a day, using a heating pad or paraffin wax (Hardy & Woodall, *JHT* 1998). The PIP joint is cobanned to a tongue depressor for full extension, or they can use their extension splint, and the heat-

ing pad is wrapped around the finger on stretch. You can do the same procedure for PIP flexion, wrapping the finger down into a fist and applying the heat. First, we have to address joint contractures, and then encourage active tendon gliding and then functional use so patients can strengthen these tissues, both bony and soft tissue, in order to safely return to work.

**Dr. Badia:** I totally agree that prevention is the best method and many of

the patients with these particular fractures can often be a little less compliant. In order to avoid problems from non-compliance or if we can't get a particular splint authorized, I just put a dorsal block cast, fiberglass, and then our therapist, Charleen Stennett, devised this sort of dorsal pad that she places under the cast. This is positioned just dorsal to the P1, proximal to the PIP joint, so that it helps place the MP joint in a bit more flexion and allows the patient to actively extend against that pad. This minimizes the PIP flexion contracture, particularly if they disappear for a few weeks. At least if they've been extending against that pad you avoid the problems where the fingers were to cup up underneath your cast or your splint where they subsequently develop a gentle flexor contracture along the length of the finger. That allows them to keep working on it actively.

**Dr. Gupta:** In flexor tendon injuries, Silverskiold showed that one of the determinants for a poor result is a lack of PIP extension at 3 weeks, and I think that's true for fractures as well. I try to get my patients' PIP joints extended certainly by 3 weeks if not by 2 weeks. I block the MP, and use rubber bands to extend the PIP joints.

**Ms. Hardy:** I think we all agree with Burkhalter (*Ft. Lauderdale Hand Clinic Newsletter*, 1991) who said, "It's far easier to regain flexion than extension" after a P1 fracture.

**Dr. Freeland:** Recovering PIP joint extension is the key to a good result.

I would like to thank the panelists. We have had an excellent discussion and I hope that our readers will find it useful in their practices. I would just like to comment that in the final determination of management, all of the factors that we've discussed must be reconciled with the education, training, experience, and especially the judgment of the treating physician. Additionally, there may be specific patient considerations that affect the decision-making process. Each patient and each fracture is considered individually. **H**

## 2006 Application for Research Grants

The AAHS Research Grant Awards were established to further the purpose of the Association as stated in its Bylaws and to foster creativity and innovation in basic and/or clinical research in all areas pertinent to hand surgery.

### Awards and Eligibility

Grants will be made for a one year period to up to three investigators. Grants are available to all AAHS members. One of the investigators must be an active or affiliate member of the association.

### Grant Application

Applications may be obtained from the AAHS website at [www.handsurgery.org](http://www.handsurgery.org), or, you can call 312-236-3307 to request a copy. Applications (an original plus seven copies) must be received by the committee chair no later than Monday, November 1, 2005, in order for the judging to be completed in time and the recipients to be announced at the Annual Meeting.

The AAHS and the Research Committee are required by the IRS to document disbursement of grant funds. Award recipients will be required to sign a letter of acceptance and submit a progress report once each year. The AAHS must be acknowledged as the source of funding in any presentation or publication. A final report must be submitted at the completion of the study. It is expected that the results of the funded research be submitted for presentation at an Annual Meeting within two years of the receipt of the award.

Funds must be returned to the AAHS if the study is not undertaken within twelve months of the receipt of the award.

Failure to follow these guidelines will disqualify the recipient from any further grant opportunities and from presenting any papers at the AAHS Annual Meeting for a period of three years following such default.

### Mail Grant Proposals to

W. P. Andrew Lee, MD  
University of Pittsburgh  
3550 Terrace Street  
Scaife Hall 690  
Pittsburgh, PA 15261



# Proximal Phalanx Fractures

The topic for this issue of *Hand Surgery Quarterly* and the Coding Corner is proximal phalanx fractures.

Because proximal phalanx fractures often occur in association with dislocations, we will also

tures of the proximal or middle phalanx have three codes associated with their care; 26740 is for closed treatment without manipulation, 26742 is for closed treatment with manipulation, and 26746 is for open treatment of an articular fracture.

MCP joint dislocations have four relevant codes. Code 26700 is for closed reduction without anesthesia, while 26705 is for closed reduction of the MCP joint with anesthesia. Percutaneous fixation of an MCP dislocation corresponds to code 26706, and open treatment is coded for with 26715.

IP joint dislocations similarly have four codes. Closed treatment without anesthesia is coded with 26770, while use of anesthesia to reduce the dislocation corresponds to 26775. Percutaneous fixation of an IP dislocation corresponds to 26775, and open treatment, including external fixation, of an IP dislocation is coded with 26785.

Another code that is relevant to this topic is code 26340. This code can be used when a finger joint is manipulated under anesthesia, as might be done to treat contractures or stiffness resulting from fractures near the MCP or PIP joints.



LEON S. BENSON, MD

### Dislocations Around the Proximal Phalanx

26700	Closed treatment of MCP dislocation, single, with manipulation, without anesthesia
26705	As above, requiring anesthesia
26706	Percutaneous skeletal fixation of MCP dislocation, single, with manipulation
26715	Open treatment of MCP dislocation, single, with or without internal or external fixation
26770	Closed treatment of IP joint dislocation, single, with manipulation, without anesthesia
26775	As above, requiring anesthesia
26776	Percutaneous skeletal fixation of IP dislocation, single, with manipulation
26785	Open treatment of IP dislocation, with or without internal or external fixation, single
26340	Manipulation, finger joint, under anesthesia, each joint

### You Code It

A 27 year old woman has her hand jerked while walking her dog. She presents with a short oblique fracture of the index finger proximal phalanx. You elect to treat it operatively and are able to close reduce the fracture and stabilize it with two percutaneous pins.

Solution: Code 26727



include codes relating to injuries of the metacarpophalangeal (MCP) and interphalangeal (IP) joints.

There are seven codes that deal with fractures of the proximal phalanx. All of these codes also apply for the same condition in the middle phalanx. Code 26720 is for closed treatment of a phalangeal shaft fracture without manipulation; if manipulation is required, the correct code is 26725.

Percutaneous pinning of the phalangeal shaft corresponds to code 26727. Code 26735 is used when the phalangeal shaft fracture is treated with an open approach (or with external fixation). Articular frac-

### Proximal Phalanx Fractures

26720	Closed treatment of phalangeal shaft fracture, proximal or middle phalanx, finger or thumb; without manipulation, each
26725	As above, with manipulation, with or without skin for skeletal traction, each
26727	Percutaneous skeletal fixation or unstable phalangeal shaft fracture, proximal or middle phalanx, finger or thumb, with manipulation, each
26735	Open treatment of phalangeal shaft fracture, proximal or middle phalanx, finger or thumb, with or without internal or external fixation, each
26740	Closed treatment of articular fracture, involving MCP or IP joint; without manipulation, each
26742	As above, with manipulation, each
26746	Open treatment of articular fracture, involving MCP or IP joint, with or without internal or external fixation, each

# Hands Free Video Recording

**T**his issue's theme involves the proximal phalanx. Proximal phalanx fractures are important for the hand surgeon because they make it difficult if not impossible to push to the "record" button on the video camera to record exciting parts of a surgical procedure on the hand, which leads to this column's topic: "hands free" video recording during hand surgery. The point of this is to automate the process of recording videos for educational presentations.



CHARLES EATON, MD

*Why would I want to record video during surgery?* If you don't routinely take pictures during surgery, automated video documentation may not have much to offer—or it may be the technology you've been waiting for. It is a wonderful way to facilitate the process of getting image documentation of interesting cases, especially for hand surgery, which is such a visual specialty. Making video recordings of your own surgery provides a great foundation for engaging presentations to either the public or your colleagues, and can provide a unique basis to critique your own surgical technique.

I operate in a small community hospital, and don't have residents or photographers. If I really want good intraoperative images, I have to take them myself, which means either taking photos myself or setting up a remote way to do this. If I take the pictures myself, I have to break from the field, and I can't always get my assistant to position the hand or the instruments the way I'd like. If I can keep my hands in the field and see the scene com-

position in a video monitor, I can arrange things exactly the way I'd like—and it saves time. Over the years, I have tried a number of "do it yourself" approaches, and will share my experience here. The goal is to accomplish this task in a way that neither changes your normal routine nor requires extra work for you—automate, automate, automate!

The primary hardware that you need is a video source, a video monitor and recording media.

**Video source:** The first decision is where to mount the video source: fixed or mobile. Fixed camera positions are either a tripod or a wall or ceiling mount. I have found it awkward and intrusive to set up a conventional camcorder in the OR along with the necessary power cord, remote control, and monitor, and I don't recommend this. A better solution is to use a webcam or surveillance camera as a standalone video source mounted on a wall or IV pole. In the low tech arena, the videocam included in the (and I'm not kidding) Lego Moviemaker is the best choice, as it has a much longer USB cord than other webcam cameras (Figure 1).



Figure 1. Screen capture from a Lego Moviemaker camera video, recorded direct a laptop.



Figure 2. Canon network camera in the operating room.



Figure 3. Wireless X10 VHS Cam mounted to surgical loupes.

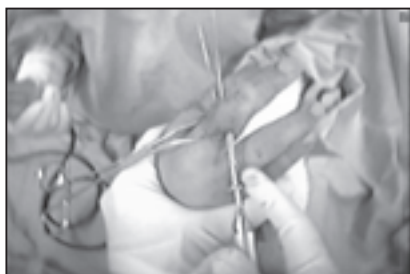However, this and most other store models lack both the resolution and the zoom to allow them to be far enough away from the operative field and still record adequate detail, so shop carefully. Two new network enabled cameras are up to the task. The first is the Canon VB-C50i, which has a 26X optical zoom lens, a 12X digital zoom and 640X480 resolution (Figure 2).

The second is the D-Link DCS-6620G Wireless G 10x Optical Zoom Internet Camera, which has less zoom but greater resolution (704x480) and has built in wireless network capability which gives greater flexibility in placement because it doesn't need a video or ethernet cable to work. Either of these cameras will record directly to

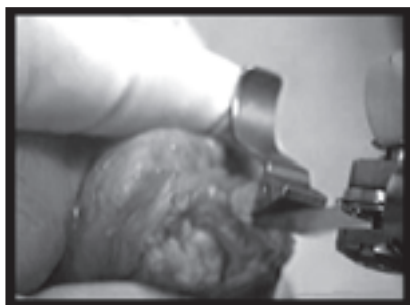a laptop or a networked computer hard drive.

Mobile camera positioning options include using a head mount, operating room light source mount, or having an assistant hold the camera. I've experimented with a few head mounted camera setups. Low end wireless surveillance cameras have been available for years, and some models like the X10 are small and lightweight enough to be mounted on a pair of surgical loupes (Figure 3).

The video stream is wirelessly relayed to a receiver which can then be recorded directly to videotape or DVD. The image resolution is poor, but adequate for some cases (Figure 4).



**Figure 4.** Video frame capture from a loupe mounted X10 cam (proximal phalanx fracture pinning).



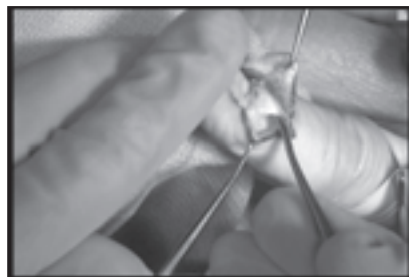
**Figure 5.** Video frame capture from a head mounted Stryker arthroscopy camera (PIP implant arthroplasty).

A better quality picture is produced by using an endoscope camera as a head mounted video source, but the native optics are problematic: too zoomed in and very narrow focal depth (Figure 5).

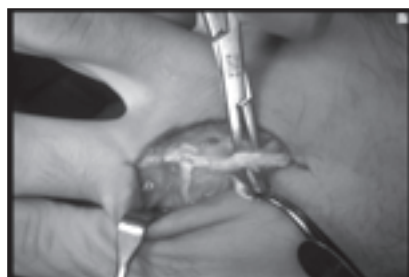
Head and loupe mounted designs have inherent drawbacks of occasionally being off center to the surgeon's field of view, susceptibility to head bob during conversation, and a feeling of restriction during

wear. The better, albeit more expensive alternative is a camera integrated into the surgical light source such as the Berchtold Chromovision In-light camera, which has a 24X zoom at 720X480 resolution (Figure 6).

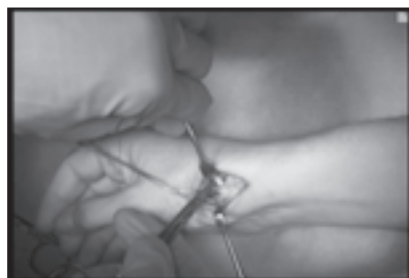With appropriate zoom settings, this provides adequate video resolution for most hand surgical procedures (Figures 7, 8, 9).



**Figure 7.** Video frame capture from Berchtold Chromovision In-Light video camera (close up – DIP arthroplasty).

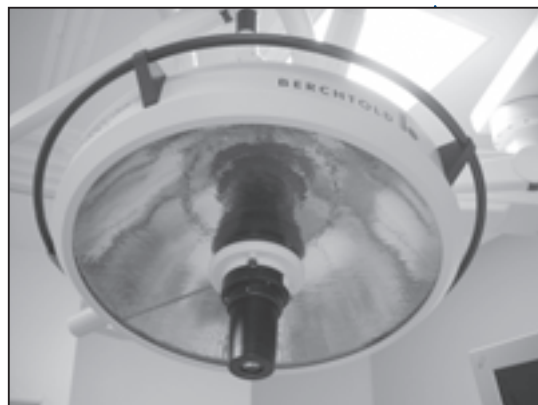

**Figure 8.** Video frame capture from Berchtold Chromovision In-Light video camera (medium zoom – sagittal band reconstruction).



**Figure 9.** Video frame capture from Berchtold Chromovision In-Light video camera (no zoom – basal joint arthroplasty)

**Video monitor:** The natural resource in the operating room is video equipment already being used for arthroscopy and endoscopy. All you have to do is provide a video source and the operating room equipment will



**Figure 6.** Berchtold Chromovision In-Light video camera.



**Figure 10.** Storz AIDA system, monitor on left, control panel on right, separated by the all important OR stereo system.

take care of the rest.

**Recording media:** Endoscopic video recording equipment is usually available and most existing systems record to VHS tape. Newer systems, such as the Storz AIDA (Figure 10), burn video and images directly to CD or DVD. The nice thing about integrated systems such as these is that all video input sources—camera, scope, fluoro—can be recorded into a single video file (Figures 11–14).

**Software:** So now you have video. How do you get it into a presentation or on your web site? If you're a video has been recorded in VHS format, you'll need to convert it to a digital format. There are many ways to do this, including outsourcing at your local media center, using computer-based utilities such as one of the Dazzle products ([pinaclesys.com/publicsite/us/Produ](http://pinaclesys.com/publicsite/us/Produ)

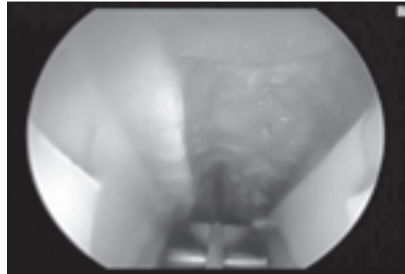
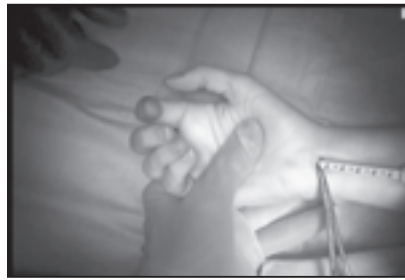*continued on page 22*

## DIGITAL HAND SURGEON

continued from page 21

cts/DazzleHome) or use a dedicated VHS to DVD conversion systems such as a Sony DVDirect DVD burner. Once this is done, you may find a hurdle in the process of converting and editing your video files to make them suitable for presentation. This is a complex topic, and your specific needs will depend on your exact hardware set up, operating system, and the exact file type (“codec”) that your video files have. A common file type is AVI, but there are many different types of AVI codecs, and you may need help from a knowledgeable colleague to sort out incompatibilities. For example, the Storz AIDA system saves files in MPG2 format, but with a proprietary codec, which may not automatically install when you view the video, and when you attempt to edit the video, result in cryptic error messages such as “not enough memory”, “page number error”, or the video may play as a black screen. The solution is usually simple, but only if you can figure out what the problem is—and it usually involves the video codec. If you want to edit your video files using free programs, the first step is probably already on your computer: Windows Movie Maker (comes with XP) or iMovie (comes with MAC OSX). Beyond that, I highly recommend two free Windows programs available on line: Rad Video Tools (radgametools.com) has a wide range of format conversion options, including MPG2 to AVI. Virtual Dub (virtualdub.org) does an excellent job of trimming and manipulating the content of video files. If you want more power, I recommend Adobe Premiere Elements. If you are converting from VHS to digital, you may not need any additional software, because usually the video hardware that attaches to your computer comes with its own software with video editing capability.

**Using it:** Once you have edited your video to the brief segment suitable for presentation, you



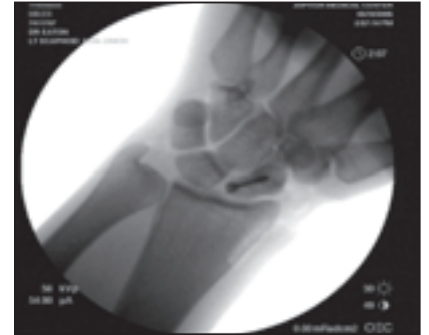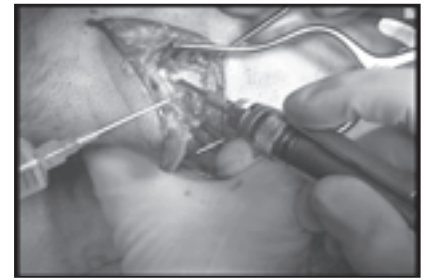**Figures 11, 12 .** Video frame captures from a Storz AIDA video file containing both external and scope views of an endoscopic carpal tunnel release.

should be able to import directly into PowerPoint for a lecture presentation. The simplest way to import video for web use is use Flash (<http://www.macromedia.com>). Flash can import video content and automatically construct a web page to play the video.

### Technical tips:

► Label your videos *inside* the video files. Once you do set up a fairly automated process of recording your surgical videos, you may wind up with quite a few videos. Although it’s much easier to scroll through DVDs than VHS tapes, it is necessary to have some kind of tracking or indexing system. If you are not good at keeping lists, I suggest the simple step of starting each video recording session with a *picture of the patient’s ID sticker and your description of the procedure*. This will allow you to browse through your digital collection and know within the first few seconds if you have the video file you’re looking for.

► Ask everyone in the operating room to watch the video as you are recording to make sure that you keep the action in the center of the camera view. The hand is usually fairly mobile on the operative field, and it’s easy, especially if you are



**Figures 13, 14 .** Video frame captures from a Storz AIDA video file containing external and five fluoro views of a vascularized scaphoid bone graft procedure.

zoomed in, to drift off screen. Having your operating room staff keep tabs on this will make it less likely that you will pop them the disc proudly, only to find that the best parts of the surgery are not in view. Not only does the field drift, but until you have some experience positioning the camera, you may find that you take long video sequences of the back of your head—something else to avoid.

► When at a particularly demonstrative juncture, do take the time to set up the field as if you are taking a still image. You can save images from the video later.

► If it’s really important, pull out your higher resolution digital camera and take pictures.

At current video resolutions of 720X480, the best images here are are tiny—just over a third of a megapixel—not in the same ballpark as even a disposable digital camera. Video resolution will probably eventually improve enough to replace still photography at some point—but at we’re not there yet. Despite that, video does have much to offer, and it’s fun—so check it out! **H**



Whether you're in the market for film processing or digital imaging, ALLPRO has exactly what you need. Two perfect options, sized, designed and priced just right for your practice.

*Too hot or cold? Not likely. But equipment that is too big, too costly or too limited for your needs is inefficient.*

Our sleek, digital ScanX12 and ALLPRO 2010 film processor work fast to deliver all cut film and plates up to

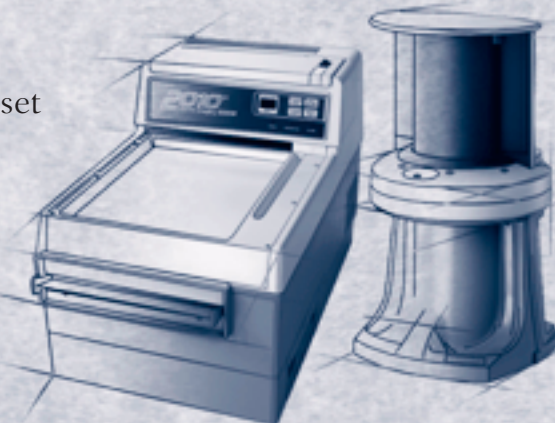
10"x12." Both are hospital grade and make small, space-saving footprints. Plus

# JUST RIGHT FOR THE HAND SURGEON

**▼ The one great Digital Option:**

*ALLPRO SCANX 12 Simplify your entire imaging process with our lean, mean ScanX12, the first 10 x 12 inch Digital Imaging System. Just right for 8 x 10 inch as well. Detail-rich images. Rapid feed system. Easy load of reusable plates in normal lighting. Perfect.*

both play nicely with your existing x-ray equipment and are child's play to set up, learn, operate and maintain by your office staff. Make a positive impression on patients and gain faster approval for treatment plans.



Experience a new level of dependability

**▲ The Leading 10 Inch Film Processor in the U.S.:**  
ALLPRO 2010 MEDICAL FILM PROCESSOR  
*The first and best 10 inch film processor also delivers 8"x10". Microprocessor electronics are unequalled for consistent, quality results. The right choice.*

based on ALLPRO's eighteen year heritage of steadfast service and support. For information, contact your authorized ALLPRO dealer or call us direct at 800.247.8324 ext 5611.

**ALLPRO IMAGING**  
THE IMAGING EXPERTS

WWW.ALLPROIMAGING.COM

# American Association for Hand Surgery Calendar

## 2005

**September 22–24, 2005**  
American Society for  
Surgery of the Hand – 60th  
Annual Meeting  
San Antonio, TX

**October 26–29, 2005**  
Bone2005  
Granada, Spain  
For more information on this  
multidisciplinary congress  
focusing on bone tissue, visit  
<http://www.bonefoundation.com/bone2005>, phone +34-95-4224095, or email [info@bonefoundation.com](mailto:info@bonefoundation.com).

## 2006

**January 11–14, 2006**  
36th Annual Meeting  
Loews Ventana Canyon  
Resort  
Tucson, AZ

**April 28–30, 2006**  
Brachial Plexus Course,  
hosted by AAHS  
Mayo Clinic  
Rochester, MN

**July 14–16, 2006**  
Mid-Year Board of Directors'  
Meeting  
The Broadmoor Hotel  
Colorado Springs, CO

**September 7–9, 2006**  
American Society for Surgery  
of the Hand – 61st Annual  
Meeting  
Washington, DC

## 2007

**January 10–13, 2007**  
37th Annual Meeting  
The Westin Rio Mar Beach  
Resort  
Rio Grande, Puerto Rico

**July 12–14, 2007**  
Mid-Year Board of Directors'  
Meeting  
Silverado Resort  
Napa, CA

## 2008

**January 9–12, 2008**  
38th Annual Meeting  
The Westin Century Plaza  
Hotel & Spa  
Beverly Hills, CA

## 2009

**January 7–10, 2009**  
39th Annual Meeting  
Grand Wailea Resort  
Wailea, Maui, HI

## 2010

**January 6–9, 2010**  
40th Annual Meeting  
Boca Raton Resort & Beach  
Club  
Boca Raton, FL

**For information contact:**

**AAHS Central Office at 312-236-3307 or [www.handsurgery.org](http://www.handsurgery.org)**

**HAND SURGERY**  
QUARTERLY



[www.handsurgery.org](http://www.handsurgery.org)  
20 North Michigan, Suite 700  
Chicago, IL 60602

## Inside This Issue:

- 1 *From the President: Mid-Year Report*
- 2 *From the Editor's Desk: Medical Illustration*
- 5 *Hand Therapy Profile*
- 6 *2006 Annual Meeting Program at a Glance*
- 9 *Leadership Profile*
- 10 *Health Volunteers Overseas Sponsorship*
- 12 *Around the Hand Table: Fractures of the Proximal Phalanx*
- 19 *Coding Corner*
- 20 *The Digital Hand Surgeon*

PRSR STD  
U.S. Postage  
**PAID**  
Documation