

# Arthroscopic Reduction and Internal Fixation for Bony Gamekeeper's Thumb

Alejandro Badia, MD; Felix Riano, MD

**Arthroscopy is an effective minimally invasive method to reduce and fix avulsed and rotated fragments from the ulnar collateral ligament of the thumb metacarpophalangeal joint.**

Lesion of the ulnar collateral ligament of the thumb is commonly seen in athletes.<sup>1</sup> It is usually due to forced radial deviation of the metacarpophalangeal joint causing damage to the structures that provide stability to the ulnar side.<sup>2</sup> These injuries may present as avulsion fractures or as tears within the substance of the ligament, or at its insertion point on the proximal phalanx. The most common pattern is an avulsion fracture at the insertion point of the base of the proximal phalanx.<sup>3</sup> Stener<sup>4</sup> described a model of injury characterized by the interposition of the aponeurosis of the

thumb adductor between the distally avulsed ulnar collateral ligament and its insertion into the base of the proximal phalanx. The Stener lesion is an operative indication for the anatomic reasons described, as is a displaced bony avulsion connected to the collateral ligament.

Several nonoperative and surgical solutions have been proposed for this problem.<sup>5-13</sup> Metacarpophalangeal arthroscopy literature is limited and is commonly related to synovectomy for diseases such as rheumatoid arthritis and hemochromatosis.<sup>14-18</sup> One report focuses on the treatment of thumb metacarpophalangeal ulnar collateral ligament tears.<sup>10</sup> We feel that the clinical usefulness of arthroscopy is best suited for avulsion fractures since the minimally invasive technique allows for dero-

tation of the fragment and a more anatomic reduction. This article reports our experience with arthroscopic treatment of bony gamekeeper's thumb.

## MATERIAL AND METHODS

Twelve patients (9 male and 3 female) with unstable bony gamekeeper's lesion were treated arthroscopically. Average patient age was 18 years (range: 16-21 years). All patients were right-hand dominant college students. The left thumb was involved in 5 patients and the right in 7 patients. The mechanism of injury in all the cases was hyperabduction of the metacarpophalangeal joint of the thumb while practicing sports. The avulsed fragment was at the insertion point of the ulnar collateral ligament on the base of the proximal phalanx in all patients. Average fragment rotation was 46° (range: 40°-60°). Fragment displacement averaged 1.5 mm (range: 2-4 mm). Surgical indications consisted of significant fragment rotation or displacement  $\geq 2$  mm. All patients under-

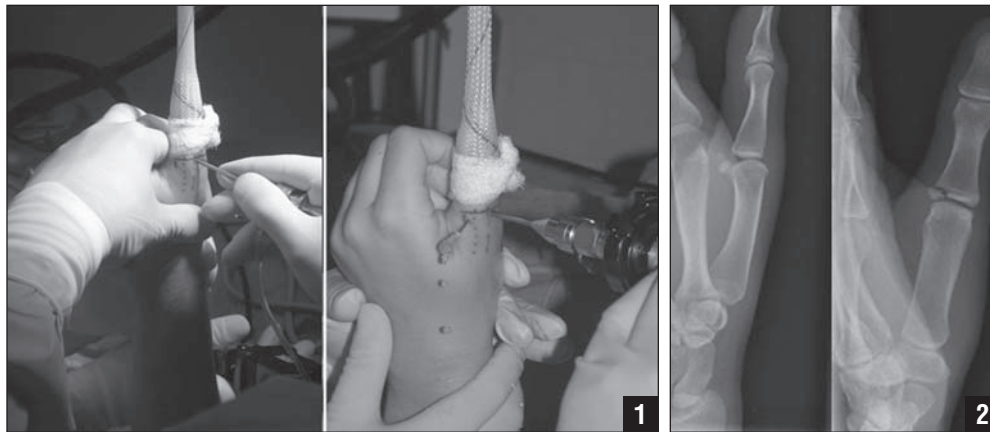
went arthroscopic assisted reduction of the avulsed fragment coupled with percutaneous pinning with a single 0.035-inch Kirschner wire followed by immobilization with a short arm thumb spica cast. Average follow-up was 34.2 months (range: 12-84 months).

## SURGICAL TECHNIQUE

The patient's hand is sterilely prepped once regional wrist block anesthesia and light intravenous sedation is achieved. Traction is achieved via a finger trap placed on the thumb with 5 lbs suspended from a shoulder holder pulley system. A traction tower is not used as this may prove cumbersome when fluoroscopy is later introduced to the operative field. One to two cc of lidocaine is introduced into the joint using an 18-gauge needle, being careful not to injure the articular cartilage of the metacarpal head. A marking pen can be used to indicate the palpable base of the proximal phalanx. A 1.9-mm 30° arthroscope is inserted via a longitu-

*Drs Badia and Riano are from Miami Hand Center, Miami, Fla.*

*Reprint requests: Alejandro Badia, MD, Miami Hand Center, 8905 SW 87th Ave, Ste 100, Miami, FL 33176.*



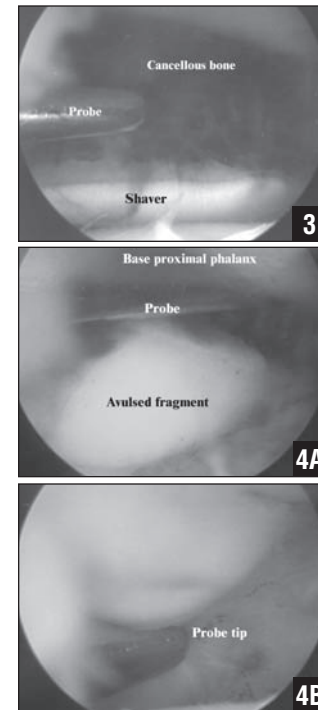
**Figure 1:** Setting and portal placement (radial to the extensor tendon). **Figure 2:** Preoperative radiographs of a 21-year-old woman softball player depicting an avulsion fracture of the ulnar collateral ligament of the left thumb.

dinal portal stab wound. This portal should be placed radial to the extensor tendon since the pathology is on the ulnar side (Figure 1). A 2.0-mm full radius shaver is initially used to remove any hematoma or minute fragments that may be initially encountered as sequelae to the fracture.

An aggressive synovectomy is then performed with emphasis on the ulnar side in order to more clearly delineate the avulsed fracture fragment. Preoperative radiographs help indicate what fracture reduction maneuver will be necessary (Figure 2); however, the arthroscopic

finding will ultimately determine the direction of fragment derotation required in order to achieve reduction and cancellous bony apposition. Usually, the probe is inserted through the ulnar portal and the fragment is hooked on its radial side within the fracture site with a gentle proximal-radial traction leading to reduction. The shaver can be inserted into the fracture site for debridement and will also assist in achieving adequate reduction without step-off or even diastasis (Figures 3 and 4). A 0.035 K-wire is then manually introduced into the joint just proximal to the

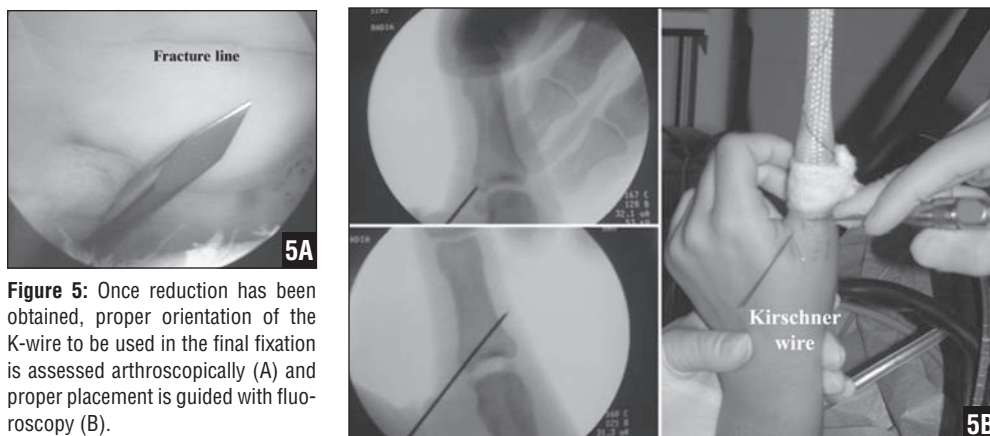
bony fragment that has been reduced. The arthroscopic view will allow the tip to be placed on the fragment with the substance of the attached collateral ligament and also determine the direction of pinning (Figure 5A). Once in place and manually held, the fluoroscope is brought in to help guide the pin as the K-wire driver is used to engage the pin on the radial cortex of the proximal phalanx distally (Figure 5B). Both fluoroscopy and arthroscopy are used to determine quality of fragment reduction as well as to confirm proper wire placement and stability (Figure 6). The



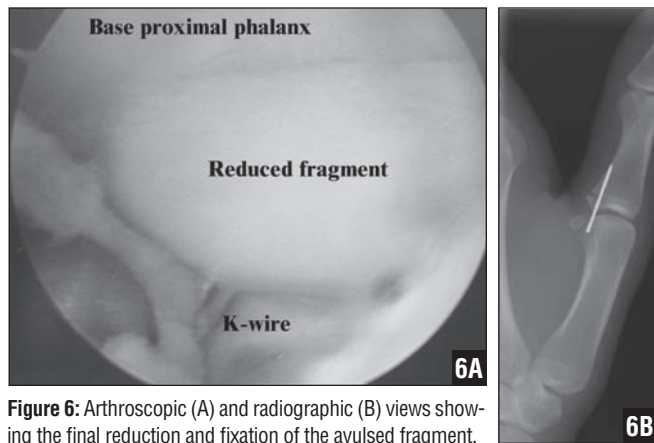
**Figure 3:** The cancellous bone area from the proximal phalanx is being debrided to prepare the surface for proper reduction of the avulsed fragment. **Figure 4:** The fragment is being manipulated (A) and reduced (B) with the probe.

wire is cut just underneath the skin and a bulky thumb spica plaster splint is applied with the thumb still suspended. Final fluoroscopic pictures are taken and the tourniquet is released.

A fiberglass thumb spica short arm cast is applied at one week postoperatively, and the pin is removed with local anesthesia at approximately 5 weeks postoperatively (Figure 7). A brief course of therapy is initiated with a hand-based CMC-type removable splint provided to the patient for use in strenuous activities. The therapy is usually minimal, as there is minimal MCP capsular swelling or stiffness as seen with open approaches. All un-



**Figure 5:** Once reduction has been obtained, proper orientation of the K-wire to be used in the final fixation is assessed arthroscopically (A) and proper placement is guided with fluoroscopy (B).



**Figure 6:** Arthroscopic (A) and radiographic (B) views showing the final reduction and fixation of the avulsed fragment.

restricted activities are permitted at 8 weeks (Figure 8).

**RESULTS**

Average tourniquet time was 15 min (range: 10-25 min). Average lateral pinch strength at final follow-up was 16 lbs (range: 14-18 lbs) and it was 98% from the unaffected side. The avulsed fragment healed in an average of 4.3 weeks (range: 4-5 weeks). Fragment healing was defined as the absence of fracture lines on the radiographic studies and lack of pain on physical examination. At final follow-up, the compromised metacarpophalangeal joint was stable to stress maneuvers performed at extension and 30° of flexion. The final metacarpophalangeal and IP range of motion were on average 0°-60° (range: 0°-65°) and 0°-88° (range: 0°-90°) respectively. No patient reported pain at final follow-up. All patients were able to return to their previous activities within 3 months.

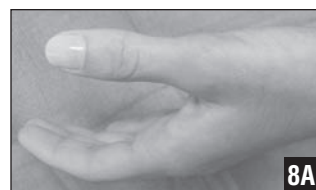**DISCUSSION**

Excessive abduction and/or extension forces applied to

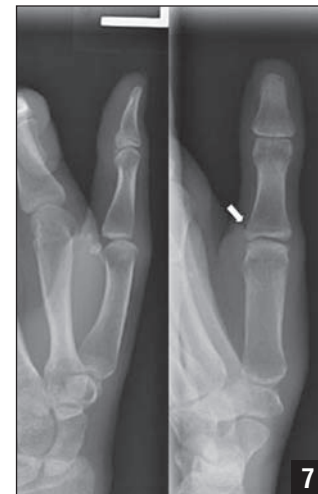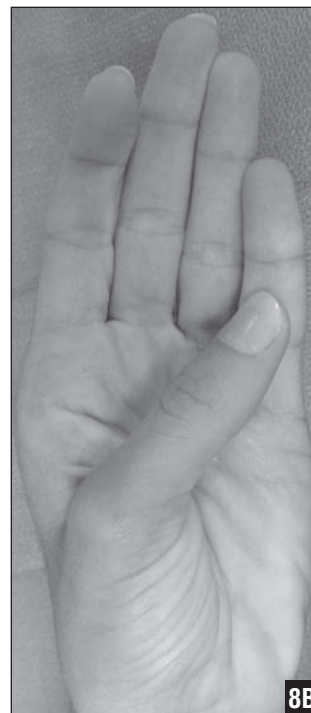the metacarpophalangeal joint of the thumb usually result in either rupture or avulsion of the ulnar collateral ligament.<sup>2</sup> In general, immobilization of the metacarpophalangeal joint has been accepted to treat acute partial ulnar collateral ligament ruptures;<sup>10</sup> however, management of complete rupture of this ligament is controversial.<sup>19-23</sup> On the other hand, avulsed and rotated fragments with significant displacement demand open reduction and internal fixation to restore stability as well as articular reduction of the fragment.

Several internal fixation techniques have been suggested for avulsion fractures at the metacarpophalangeal joint.<sup>1,4,11,13,23</sup> Kozin and Bishop<sup>11</sup> reported treating avulsion fractures of the thumb ulnar collateral ligament in

**Figure 8:** Cosmetic and functional appearance of the thumb at final follow-up

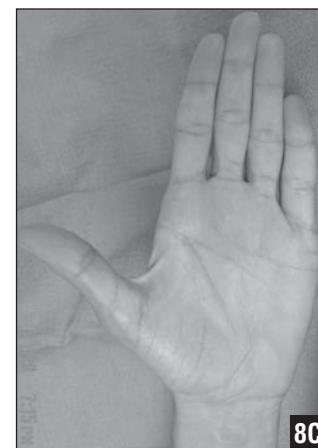

7 patients and the radial collateral ligament in 2 patients with open reduction and tension wire fixation. All injuries were treated within two weeks from original trauma. The avulsion occurred from the volar aspect of the proximal phalanx in every case. Average fragment rotation was 47°. In their study, to obtain satisfactory fragment reduction it was necessary to incise both the adductor aponeurosis and the joint capsule to achieve proper visualization of the articular surface. Average fracture healing time was 6 weeks. At final follow-up (26 months) all the thumbs displayed good stability in extension and 30° of flexion. The metacarpophalangeal and IP motion averaged 77% and 97% of contralateral side respectively. Pinch strength averaged 97% from opposite thumb.



**Figure 7:** Radiographic studies obtained at the time of pin removal (5 weeks) showed complete fracture healing (arrow).

Small-joint arthroscopy has become commonplace in the surgeon's armamentarium; however, use of this method in the metacarpophalangeal joints has been mainly focused on treating inflammatory conditions by performing synovectomy.<sup>14-18</sup> Treatment of a soft-tissue ulnar collateral ligament tear has also been managed arthroscopically. Ryu and Fagan<sup>10</sup> reported on 8 patients with Stener lesions in the thumb treated arthroscopically. According to the surgical description, retrieval of



the distal end of the ligament was achieved by introducing a probe between the inner wall of the thumb adductor and the metacarpal head. Then, they placed it at its insertion point at the base of the proximal phalanx without securing it. The metacarpophalangeal joint was held in 20°-30° of flexion by crossing it with a single 0.045-inch K-wire. They followed the patients for an average of 39 months and obtained the following results: pinch strength of 19 lbs, no appreciable metacarpophalangeal laxity, IP motion of 102° and metacarpophalangeal motion of 51°.

We used arthroscopy to treat 12 patients with unstable bony gamekeeper's lesion. Our technique differed from Ryu and Fagan's<sup>10</sup> in that fixation of the avulsed fragment was performed with a 0.035-inch K-wire and we did not have to cross the metacarpophalangeal joint. Healing of the fracture in our series occurred faster (4.3 weeks). The final pinch strength was on average 16 lbs corresponding to 98% of the opposite thumb. Range of motion for the metacarpophalangeal and IP joints was 0°-60° and 0°-88° respectively. At final follow-up, complete metacarpophalangeal joint stability was achieved to stress maneuvers in extension and 30° of flexion.

There are various advantages to arthroscopic assisted reduction and percutaneous fixation of the avulsed fragment when compared to open reduction. First, by using this technique there is no need

to violate the joint capsule to achieve reduction, hence it is feasible to shorten the rehabilitation period. Total surgical and tourniquet time are shorter compared to open reduction. Less scarring is involved, including a better cosmetic appearance without sacrificing function or stability as the main goals of the surgical procedure. Finally, thorough assessment of the entire joint surface prevents any residual articular step-off. Irrigation of the joint allows for a decreased postoperative inflammatory response while allowing removal of any small osteochondral fragments that might remain inside the joint acting as a persistent irritant. One can also address chondral lesions encountered and perform shrinkage capsulorrhaphy if the attached ligaments are attenuated or partially torn.

### CONCLUSION

Gamekeeper's thumbs with a bony fragment are better managed with an arthroscopic reduction. The advantages of arthroscopic versus open techniques are similar to those experienced in larger joints, and we therefore recommend this technique for the treatment of displaced bony gamekeeper's lesions that require reduction. □

### REFERENCES

1. Frykman G, Johansson O. Surgical repair of rupture of the ulnar collateral ligament of the metacarpo-phalangeal joint of the thumb. *Acta Chir Scand.* 1956; 112:58-64.
2. Kuz JE, Husband JB, Tokar N,

- McPherson SA. Outcome of avulsion fractures of the ulnar base of the proximal phalanx of the thumb treated nonsurgically. *J Hand Surg Am.* 1999; 24:275-282.
3. Glickel SZ, Barron OA, Eaton RG. Dislocations and ligament injuries in the digits. In: Green DP, Hotchkiss RN, Pederson WC, eds. *Operative Hand Surgery.* 4th ed. New York, NY:Churchill Livingstone; 1999:772-808.
4. Stener B. Displacement of the ruptured ulnar collateral ligament of the metacarpo-phalangeal joint of the thumb. A clinical and anatomical study. *J Bone Joint Surg Br.* 1962; 44:869-879.
5. Campbell JD, Feagin JA, King P, Lambert KL, Cunningham R. Ulnar collateral ligament injury of the thumb. Treatment with glove spica cast. *Am J Sports Med.* 1992; 20:29-30.
6. Gerber C, Senn E, Matter P. Skier's thumb. Surgical treatment of recent injuries to the ulnar collateral ligament of the thumb's metacarpophalangeal joint. *Am J Sports Med.* 1981; 9:171-177.
7. Glickel SZ, Malerich M, Pearce SM, Littler JW. Ligament replacement for chronic instability of the ulnar collateral ligament of the metacarpophalangeal joint of the thumb. *J Hand Surg Am.* 1993; 18:930-941.
8. Kozin SH. Treatment of thumb ulnar collateral ligament ruptures with the Mitek bone anchor. *Ann Plast Surg.* 1995; 35:1-5.
9. Neviaser RJ, Wilson JN, Lievano A. Rupture of the ulnar collateral ligament of the thumb (gamekeeper's thumb). Correction by dynamic repair. *J Bone Joint Surg Am.* 1971; 53:1357-1364.
10. Ryu J, Fagan R. Arthroscopic treatment of acute complete thumb metacarpophalangeal ulnar collateral ligament tears. *J Hand Surg Am.* 1995; 20:1037-1042.
11. Kozin SH, Bishop AT. Tension wire fixation of avulsion fractures at the thumb metacarpophalangeal joint. *J Hand Surg Am.* 1994; 19:1027-1031.
12. Pichora DR, McMurtry RY, Bell MJ. Gamekeepers thumb: a prospective study of functional bracing. *J Hand Surg Am.* 1989; 14:567-573.
13. Jupiter JB, Sheppard JE. Tension wire fixation of avulsion fractures in the hand. *Clin Orthop Relat Res.* 1987; 214:113-120.
14. Sekiya I, Kobayashi M, Taneda Y, Matsui N. Arthroscopy of the proximal interphalangeal and metacarpophalangeal joints in rheumatoid hands. *Arthroscopy.* 2002; 18:292-297.
15. Slade JF III, Gutow AP. Arthroscopy of the metacarpophalangeal joint. *Hand Clin.* 1999; 15:501-527.
16. Rozmarny LM, Wei N. Metacarpophalangeal arthroscopy. *Arthroscopy.* 1999; 15:333-337.
17. Declercq G, Schmitgen G, Verstreken J. Arthroscopic treatment of metacarpophalangeal arthropathy in haemochromatosis. *J Hand Surg Br.* 1994; 19:212-214.
18. Vaupel GL, Andrews JR. Diagnostic and operative arthroscopy of the thumb metacarpophalangeal joint. A case report. *Am J Sports Med.* 1985; 13:139-141.
19. Coonrad RW, Goldner JL. A study of the pathological findings and treatment in soft-tissue injury of the thumb metacarpophalangeal joint. With a clinical study of the normal range of motion in one thousand thumbs and a study of post mortem findings of ligamentous structures in relation to function. *J Bone Joint Surg Am.* 1968; 50:439-451.
20. Louis DS, Huebner JJ Jr, Hankin FM. Rupture and displacement of the ulnar collateral ligament of the metacarpophalangeal joint of the thumb. Preoperative diagnosis. *J Bone Joint Surg Am.* 1986; 68:1320-1326.
21. Smith RJ. Post-traumatic instability of the metacarpophalangeal joint of the thumb. *J Bone Joint Surg Am.* 1977; 59:14-21.
22. Bowers WH, Hurst LC. Gamekeeper's thumb. Evaluation by arthrography and stress roentgenography. *J Bone Joint Surg Am.* 1977; 59:519-524.
23. Frank WE, Dobyns J. Surgical pathology of collateral ligamentous injuries of the thumb. *Clin Orthop Relat Res.* 1972; 83:102-114.

Section Editor: Steven F. Harwin, MD